

### Anatomy 1.1a&b (A&P compared)

#### 1.1a ANATOMY

Microscopic Anatomy= Unseen

Cytology study of = body cells

Histology study of = tissue

Types of Gross Anatomy = Systemic, Regional, Surface, Comparative, Embryology

Pathological Anatomy= Anatomic disease caused by disease

Radiographic Anatomy = Observes internal structure

Types of Radiographic Anatomy= MRI & X-Ray

#### 1.1b PHYSIOLOGY

physiology= Function

Physiology Types= Cardiovascular, Neurophysiology, respiratory, reproductive, and pathophysiology

### Anatomy 1.2 (A&P Integrated)

Form and Structure= interrelated

Physiologists focus on= mechanisms and Structure

Anatomists focus on= form and structure

### Anatomy 1.3abc (Body's organization)

#### 1.3a=LIVING CHARACTERIZATION

Metabolism = All chemical reaction in the body

Metabolism has= Anabolism & Catabolism

7 traits makes Alive= Reproduces, Grows, Develops, Uses Energy, Responsiveness, Adapts, and moves

#### 1.3b = ORGANIZATION OF ORGANISMS

Organization= Atom, Molecule, Chemical, Organelle, Cells, Tissue, Organ, Organ System, Organism

#### 1.3c= ORGAN SYSTEMS

Integumentary System = skin

Muscular System= muscle

Skeletal System= Skeleton

Nervous System= Nerves

Endocrine System= Hormones

Lymphatic System= Lymph

Cardiovascular System= Blood Vessels

Respiratory System= Lungs

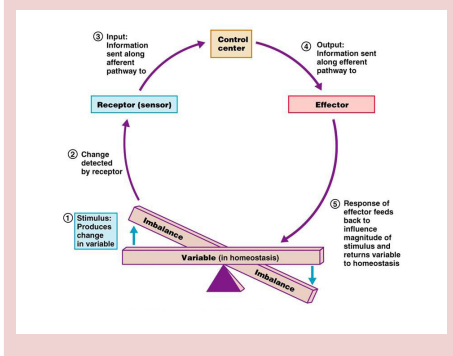
Urinary System= Liquid Waste

Male Reproductive System= Male Sex

Digestive System= Solid Waste

Female Reproductive System= Female Sex

### Image



### Anatomy 1.4 abcdef (A&P Terminology)

#### 1.4a= ANATOMIC POSITIONS

3 Planes= Frontal, Transverse, Midsagittal

#### 1.4b= EHHH

#### 1.4c= ANATOMIC DIRECTIONS

Relative to front & back= Anterior, Posterior, Dorsal, and Ventral

Relative to Head= Superior, Inferior, Cranial, Caudal, and Rostral

Relative to Middle= Medial, Lateral, Deep, and superficial

Relative to attachment= Proximal and Distal

#### 1.4d =REGIONAL

Axial= head, neck, and trunk

Appendicular region= upper/lower limbs

#### 1.4e= CAVITIES

Ventral Cavity= Superior (Thoracic) & Inferior (abdominopelvic)

Ventral Cavity lined with= Serous membrane



### Anatomy 1.4 abcdef (A&P Terminology) (cont)

Serous Membrane= Parietal layer & Visceral Layer

Serous membrane contains = Serous Fluid

Heart (Inner to outer layers) Heart, Visceral pericardium, pericardial cavity with serous fluid, and parietal pericardium

Lungs (Inner to outer layers) Lungs, Visceral Pleura, Pleural cavity with serous fluid, parietal pleura, diaphragm

Abdominopelvic cavities= up=abdominal cavity, down=pelvic cavity

Abdominopelvic cavity (inner to outer)= Visceral peritoneum, peritoneal cavity, parietal peritoneum

### 1.4f ABDOMINOPELVIC REGIONS & QUADRANTS

abdominopelvic regions= Umbilical, epigastric, hypogastric, right/left hypochondriac, left/right lumbar, right and left/ iliac

### Anatomy 1.5 ABC

#### 1.5a HOMEOSTASIS COMPONENTS

Order = Stimulus, Receptor, control center, effector, homeostasis restored

#### 1.5b NEGATIVE FEEDBACK

### Anatomy 1.5 ABC (cont)

Negative feedback= decrease

#### 1.5c POSITIVE FEEDBACK

Positive Feedback increase

### Anatomy 1.6 Health & Disease

