General

Plasma	matrix of blood, clear light yellow fluid 55%
Buffy Coat	made of leukocytes and platelets <1%
Erythrocytes	RBC's, 45%
Hematocrit	percentage of blood volume composed of RBC's
Hemoglobin	protein in RBC that carries oxygen, 4 protein chains (globins) that bind co2 and 4 heme groups that bind o2 to iron
Hemostasis	the cessation of bleeding, stopping fatal leaks
Hemorrhage	excessive bleeding

Interior of the Heart

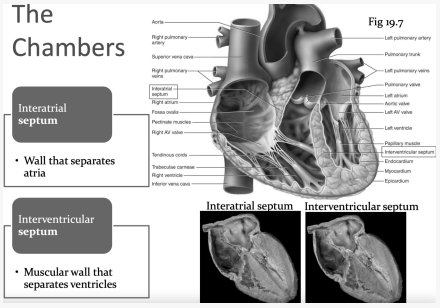

Platelets and Hemostasis

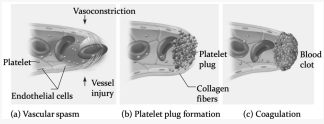

Exterior of the Heart

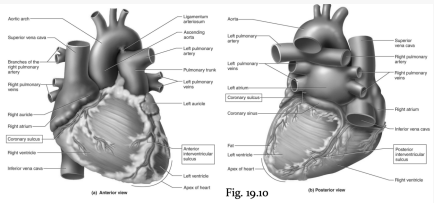

Walls of the Heart

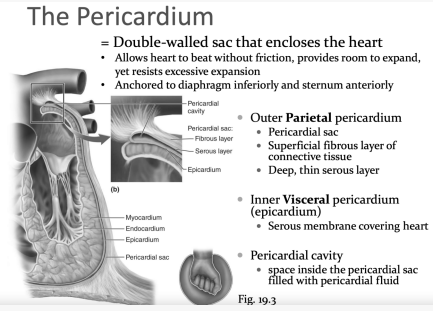

Left Arterial Supply

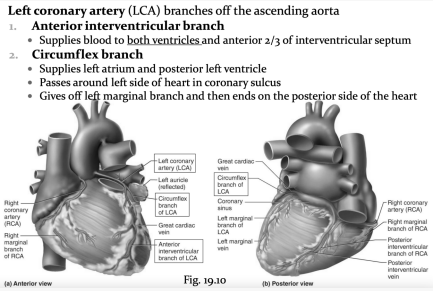

Cardiac Veins

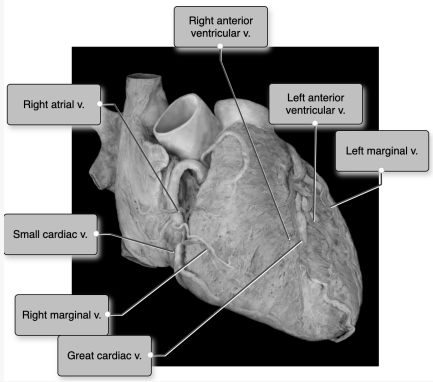

Erythrocytes

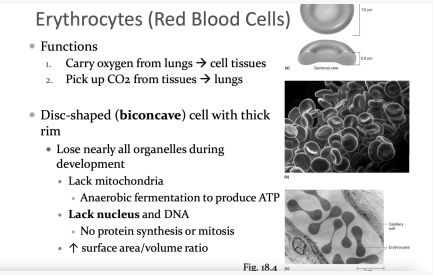

Erythrocyte Disorders

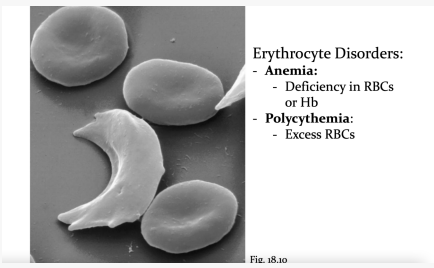

Electrical Conductivity

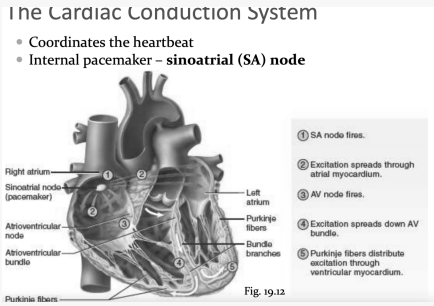

Layers of the Heart (Epi, Endo, Myo)

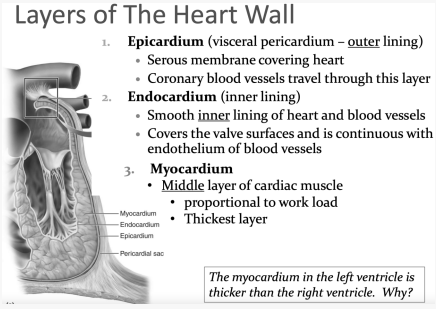

Position, Size, and Shape of Heart

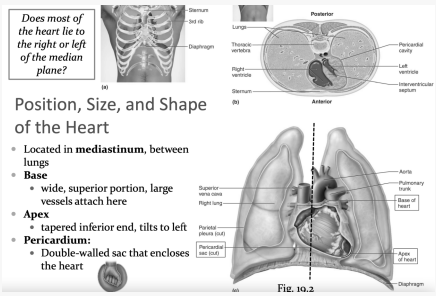

Sponsored by ApolloPad.com
Everyone has a novel in them. Finish Yours!
https://apollopad.com

Right Arterial Supply

- **Right coronary artery** (RCA) branches off the ascending aorta
  - Supplies right atrium and sinoatrial node (pacemaker)
  1. **Right marginal branch**
     - Supplies lateral aspect of right atrium and ventricle
  2. **Posterior interventricular branch**
     - Supplies posterior walls of ventricles

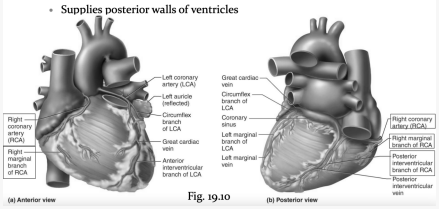

Fig. 19.10

WBC Disorders

White Blood Cells

White Blood Cell Disorders:
- **Leukopenia**:
  - low white blood cell count (<5000/ul)
    - Lead, arsenic, mercury poisoning
    - Radiation sickness
    - Infectious diseases (i.e. AIDS)
- **Leukocytosis**:
  - high white blood cell count (>10000/ul)
    - Infection, allergy
- **Complete Blood Count** (CBC):
  - # RBCs, # WBCs, platelets and relative #s of WBCs
  - Hematocrit, Hb content, RBC size
- Leukemia:
  - Cancer of hemopoietic tissues
    → abnormally high number of circulating leukocytes

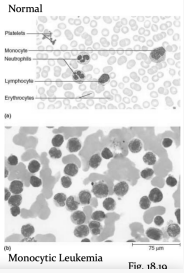

Monocytic Leukemia
Fig. 18.19

Leukocytes WBC

Leukocytes (White Blood Cells)

- Least abundant formed elements
- Conspicuous nuclei
  - violet to dark purple in blood stains
- Retain their organelles
- More abundant in connective tissues

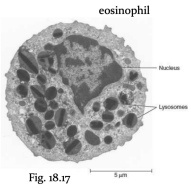

Fig. 18.17

1. Granulocytes
2. Agranulocytes

Venous Heart Drainage

Heart Venous Drainage:
Route by which blood leaves the heart

- 5-10% of coronary blood drains directly into heart chambers (mostly right ventricle)
- Most coronary blood returns to right atrium by way of the **coronary sinus** which has three main inputs:
  1. **great cardiac vein**
  2. **posterior interventricular** (middle cardiac) **vein**
  3. **left marginal vein**

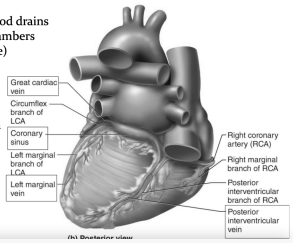

Granulocytes

- Contain **specific granules** that stain conspicuously and distinguish cell types

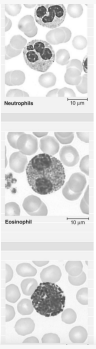

1. **Neutrophils** (60-70%):
   - Polymorphonuclear leukocytes
   - Barely visible granules in cytoplasm
   - 3-5-lobed nucleus
2. **Eosinophils** (2-4%):
   - Large rosy-orange granules (eosin)
   - bilobed nucleus
3. **Basophils** (<1%):
   - Large, abundant, violet granules (methylene blue) (obscure a large S-shaped nucleus)

Blood Flow through the Heart

Blood Flow Through the Chambers

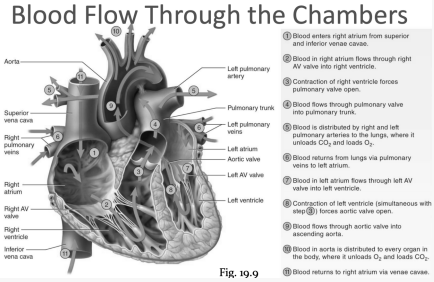

Fig. 19.9

Aganulocytes

Agranulocytes

Do not contain **specific granules**

1. **Lymphocytes**
   - 25-33%
   - Variable bluish cytoplasm
   - Ovoid/round
   - Uniform dark violet nucleus

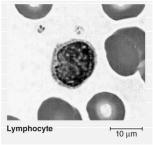

2. **Monocytes**
   - 3-8%
   - Usually largest WBC
   - Ovoid
   - Kidney-, or horseshoe-shaped nucleus
   - Differentiate into **macrophages** in tissue

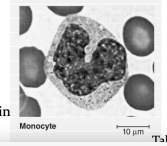

Sponsored by **ApolloPad.com**
Everyone has a novel in them. Finish Yours!
https://apollopad.com