

Causes of TMD

Functional - extra-articular (muscle imbalance - Trps in masticatory muscles)

Structural - intra-articular (tears of the disc, arthritis) - TRUE TMD

Psychological factors - Bruxism

Occlusal disturbances

Risk Factors

Female

Bruxism

Gum Chewing

Jaw Play - stretching/moving jaw alot

Arm leaning

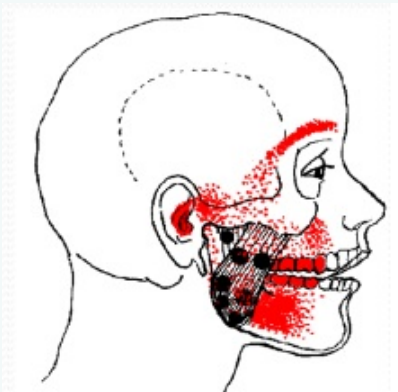Somatisation

Life Dissatisfaction

Negative Psychological symptoms

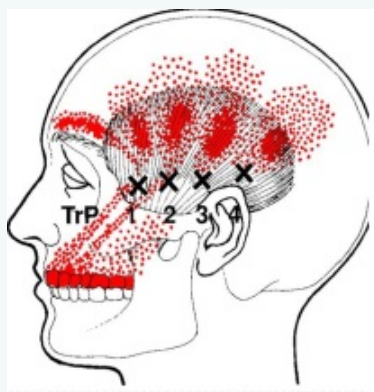
Muscles of Mastication + Trigger points

Masseter



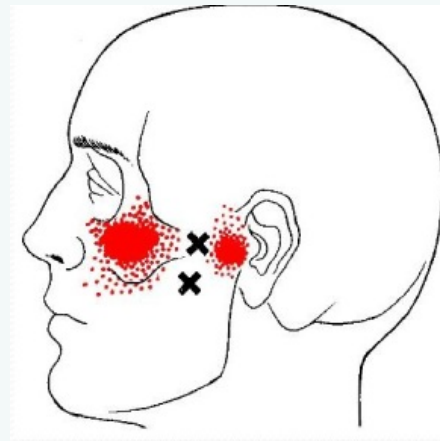
Elevates Mandible

Temporalis



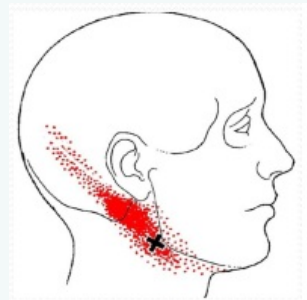
Attaches onto coronoid process - Elevates mandible

Lateral Pterygoid



Protrusion + Anterior translation of disc condyle - activates too early in opening of the jaw in TMD. Intraoral TrP therapy

Digastric



Depressor - posterior draw/stabilisation of the TMJ
Underactive in TMD

Muscles imbalances

Tight	Weak
Elevators & Protruders	Depressors & Retractors
Masseters	Digastric
Medial & Lateral Pterygoid	Suprahyoid muscles
Temporalis	

RED FLAGS

New/Abrupt onset of pain >50y

Progressively severe

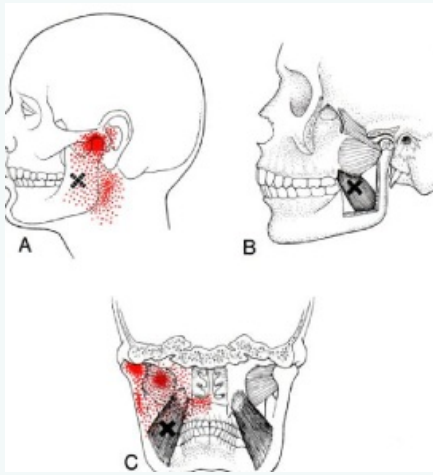
Sleep loss due to pain

Systemic symptoms

Neurological S&S

Trauma

Medial Pterygoid



Elevates Mandible - forms a tendinous sling around the angle of mandible, Trp work done intra-orally

C

By **Siffi** (Siffi)
cheatography.com/siffi/

Published 3rd August, 2021.
Last updated 17th July, 2021.
Page 1 of 3.

Sponsored by **CrosswordCheats.com**
Learn to solve cryptic crosswords!
<http://crosswordcheats.com>

Examination

Rule out other pathologies

Dental pain

Neck Pain + headaches

Clicking

ROM

Bruxing

Parafunctional habits

Ear disorders

Hx of trauma (Transient capsulitis)

Physical Exam

ROM (normal = 45-55mm)

Movement patterns

Condylar exclusion

Centric relation test (pain in joint = intra-articular pathology)

Palpate muscles of mastication

Occlusion/dentition

Cx spine - look for upper crossed

Management

Advice:

Soft diet

Avoid Stimulants

Keep lips together, teeth apart + tongue up

Upright posture - head retracted

Chew bilaterally

Avoid gum chewing & grinding

Avoid prone sleeping

Avoid excessive mouth opening, lip biting, self manipulation, jaw stretching, fingernail biting

Treatment

NSAIDs/Paracetamol

SMT, Mobilisation of the TMD

Release tight muscles (PIR, TPT, MFR)

Stabilisation exercises

Correction of posture

Advanced

Splint therapy

Relaxation therapy

Acupuncture

Special Imaging

Occlusal therapy

Joint disturbances

Anterior Disc Displacement

Recapture of an anteriorly displaced disc

Causes - clicking + lateral deviation

Sometimes, condyles cannot recapture the disc - reduced ROM

OA

RA

Occlusal imbalance

Disc tear/crack

Causes of Bruxism

Sleep Apnoea (Dry mouth causes teeth grinding to create saliva)

Alcohol and stimulants

Tobacco

Stress/Anxiety

Sleep disturbance

Abnormal occlusion

Normal/abnormal movement patterns

Normal

Tip of chin moves in a continuous, smooth line

Goes inferiorly & Posteriorly

Abnormal

Tip of the chin - moves in a non-smooth, non-continuous line

Protrusive movement/lack of posterior glide

