Classfiications

Congenital: VB malformation at birth

Secondary: Another disorder (spinal muscular dystrophy)

Idiopathic: Cause not known - multiple factors - sometimes genetic (children born to older mothers)

Subclassfications:
0-5 years of age: Congenital
6-12 years of age: Early onset scoliosis
13-18 years of age: Adolescent idiopathic scoliosis

Congenital: Includes infantile idiopathic scoliosis - develops within first 2 years - more common in boys - left tx curve, 75% resolve

Early onset: Mimics adolescent version - more common in females - right tx curve **high degree of progression** - Neural axis abnormalities (Chiari)

Adolescent idiopathic: Most common - insidious - chance of progression increases in relation to the curve (large) and decreases in proportion to skeletal maturity (skeletal mature patients) and double/multiple curves

Risse's sign

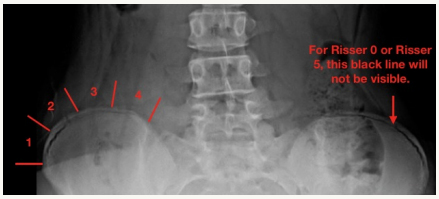

Above X-ray showing someone that still is not skeletally mature <14-17 years old in women and <18-22 in men

Cobb's Angle

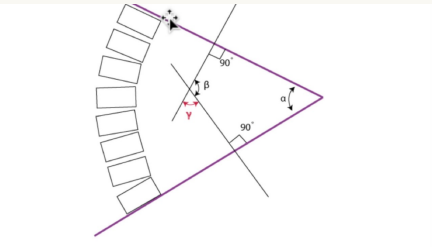

Progression factor = (Cobb angle - (3x Risser sign)/Patient's age)

Sponsored by **Readable.com**
Measure your website readability!
https://readable.com

Presentation

- Parents notice deformity of their child and get worried - child often has problems with their bodily image
- Only few present with back pain (some have underlying causes)
- Triples chance of back pain in adulthood
- High angle Tx curves (>50°) may impair respiratory function and curves >90° can lead to cardiorespiratory failure
- Make note of curvature, angle of curve, rib humps, scapula protrusion (right tx most common-right shoulder higher and rotated anterior with right scapula winging)
- Ask about clue in skeletal maturity and family links
- Palpate - hamstrings, psoas,paraspinals

Adam's forward bending: differentiates structural from functional, Structural the rib hump stays, functional it disappears when flexing forward

- LL discrepency
- Neuro of LL and UL
- Vitamin D deficiency can cause scoliosis (screen)

Imaging



Criteria:
Cobb angle >10° and axial rotation of vertebral bodies
Radiographs should be performed yearly in Rissers stage 0-3 and every 18 months in stage 4-5. (P-A views to reduce leukemia, GI, lung and breast cancers)
Early onset should be monitored every six months
MRI to check for chiari and neural axis

Management

- Stop curve progression
- Manipulation and myofascial release, bracing
- EMT of SI joints
- Core stability exercises and SEAS
- Bracing (curves between 30 and 40 ^{o} in patients who are still growing
- <0.3% of all scoliosis cases require surgical correction

Sponsored by **Readable.com**
Measure your website readability!
https://readable.com