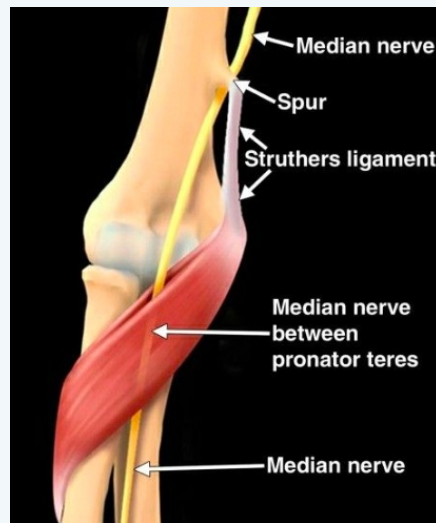


### Pronator Teres



- Compression of median nerve by pronator teres
- Median nerve innervates most of the flexor muscles of the forearm and hand
- Sensation to volar forearm and first 3 and a half digits

### Path

- Median nerve passes through cubital fossa at forearm
- Passes beneath bicipital aponeurosis and arch of the FDS
- Passes between superficial and deep heads of the pronator teres

### Causes

- Prolonged/repetitive forearm pronation and finger flexion (gripping with palm down)
- More common in dominant arm
- Usually in fifth decade
- Four times more common in women
- Diabetes, alcoholism or hypothyroidism increases risk

### Hx

- Aching discomfort in volar forearm
- Paresthesia in first three and a half digits
- Can present similar to CTS (nocturnal pain usually absent and symptoms increase in repetitive/resisted forearm supination/pronation in PTS)



By **Siffi (Siffi)**  
[cheatography.com/siffi/](https://cheatography.com/siffi/)

Not published yet.  
Last updated 8th May, 2021.  
Page 1 of 3.

Sponsored by **CrosswordCheats.com**  
Learn to solve cryptic crosswords!  
<http://crosswordcheats.com>

### PE

- TTP over pronator teres, medial epicondyle
- +ve Tinel sign (proximal anterior forearm)
- -ve Phalans/Tinels at carpal tunnel
- +ve Pronator Teres test
- Weakness of FPL, FDP, Pronator Quad - grip
- Assess for Cx radiculopathy - weakness of wrist extensors and triceps
- Assess for other areas of entrapment (see below)

### Sites of entrapment

**Ligament of Struthers** - Anatomical variant (1%)

Ligament attaches from supracondylar process to the medial epicondyle

Palpate distal humerus (5cm proximal to medial epicondyle)

**Thickened bicipital aponeurosis** - Occurs in resisted elbow flexion (120-130 degrees) with the forearm in maximal supination

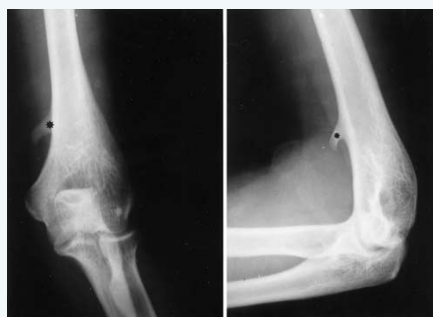**Thickened proximal edge of the arch of the FDS** - Resisted flexion of middle finger

**AINS** Anterior interosseous nerve - branch of the median nerve gets entrapped **purely motor** unable to do "ok" sign

### DDx

- Double crush
- Cx arthropathy
- Cx disc
- Brachial plexus neuritis
- TOS
- CTS
- Cubital tunnel entrapment

### Imaging



Above image shows supracondylar process on x-ray

- X-ray if supracondylar process, deformity, ff#, neoplasm
- MRI - tumours, cysts, osseous spurs, anatomical variants
- US



### Management

- Rest
- Nerve gliding exercises
- Avoid repetitive/forceful gripping
- Splint if severe for two weeks
- Night splint
- Cryotherapy over pronator teres
- US (15 mins 1MHz, 1 watt 25% duty cycle) and elec stim
- Stretching and myofascial release of hypertonic pronator teres and wrist flexors
- Sx if failure to respond to conservative care within 4 months

C

By **Siffi** (Siffi)  
[cheatography.com/siffi/](https://cheatography.com/siffi/)

Not published yet.  
Last updated 8th May, 2021.  
Page 3 of 3.

Sponsored by **CrosswordCheats.com**  
Learn to solve cryptic crosswords!  
<http://crosswordcheats.com>