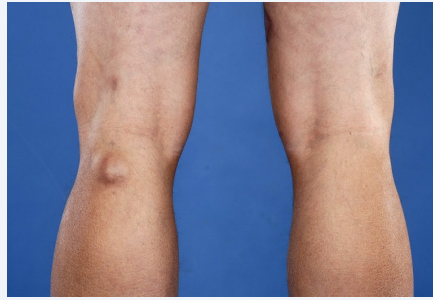

Baker's cyst



- Benign swelling of popliteal bursa from extra synovial fluid in the knee joint capsule

Causes

- OA
- Meniscus injuries
- Herniation of knee joint capsule (tear of meniscus)
- No hx of trauma

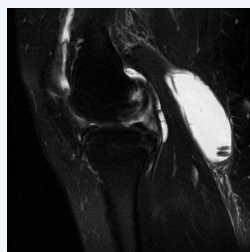
Presentation

- Soft, cystic swelling/fullness in popliteal fossa at medial femoral condyle
- Usually inbetween semimembranosus and medial head of gastro
- Pain aggravated by knee extension/fully flexed
- Swelling of calf muscles
- Can just present as pain behind the knee

DDx

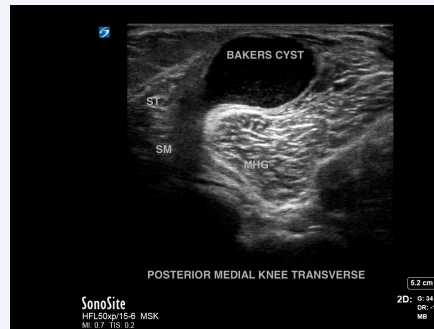- DVT
- Medial gastroc strain
- Soft tissue neoplasm
- Superficial phlebitis

Imaging



- US (to assess intraarticular pathology)
- MRI (if other pathologies are suspected)
- RA screen

Imaging - US



Baker's cyst on an US

Management

- Treat underlying cause
- Rest and leg elevation
- Electrotherapy and ice
- Stretching of hamstrings, quads, gastroc, ankle dorsiflexors
- Avoidance of squatting, kneeling, heavy lifting, climbing or running
- Can be aspirated and treated with steroid injection if big/painful
- Baker's cyst in children usually disappear over a period of time

C

By **Siffi (Siffi)**
cheatography.com/siffi/

Not published yet.
Last updated 7th May, 2021.
Page 2 of 2.

Sponsored by **Readable.com**
Measure your website readability!
<https://readable.com>