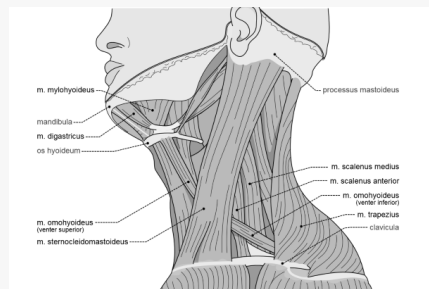
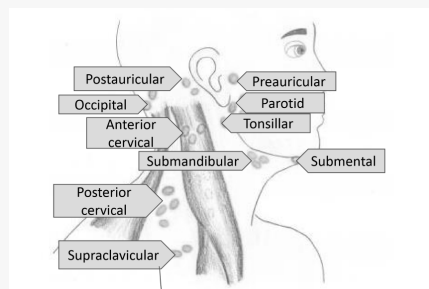


Anatomy in the neck



Lymph nodes
 Thyroid + parathyroid gland
 Salivary Gland
 Blood Vessels
 Muscles, bones, cartilage
 Nerves
 Oesophagus + trachea

Cervical Lymphnodes



Non-MSK causes of neck pain

Oesophagus: Indigestion, Difficulty swallowing

Thyroid: Enlargement, Infection/Inflammation, cancer

Carotid Artery: Dissection

Lymph nodes: Infection/inflammation, cancer - Submental, Submandibula, Tonsillar, Parotid, Preauricular, Postauricular, Occipital, Anterior cx, P

Heart: MI/IHD - refer to neck and jaw + down left arm

Lung: Apical Tumours - refer to neck, shoulder and arm

- Consider

Age, Hx of the lump, Location of the lump, Exam of the lump, Exam of the head/neck



By **Siffi** (Siffi)
cheatography.com/siffi/
ko-fi.com/siffi7625

Not published yet.
 Last updated 14th November, 2021.
 Page 1 of 7.

Sponsored by **Crossw**
 Learn to solve cryptic c
<http://crosswordcheats>

Questions to ask

Pain related to exertion, relieved by rest? Risk factors of IHD/Cardiac issues

Respiratory symptoms? Smoker?

Swellings in the neck? (lymphnodes/thyroid?) - How long? Where is it? How was it noticed? Enlarging or changing? Local symptoms? Other symptoms? Cancer? Smoking/alcohol? Travel/trauma?

GI Symptoms?

Hx of neck traum/headache/visual disturbances/neurological symptoms?

Recent infections/ hx of cancer?

- Lumps should reduce within 6 weeks , if not, consider possible malignancy (should be seen within 2 weeks)
- Painful nodes = infection
- Firm, hard, painless = cancer

Neck Pain Causes

- Pain from superior nuchal line to the tip of T1 , sagittal planes

Caused by:

Myofascial Pain Syndrome

Intervertebral Joint Hypomobility

Spondylosis

Musculoligamentous strain/sprain

Intervertebral Disc Derangement

Serious Disorders

Meningitis/SAH

Angina/MI referral

Metastasis

Vascular Lesions

Oesophageal Disorders

Pitfalls

RA

PMR

Fibromyalgia

Myelopathy - look for stiffness of the legs

Lumps:

Children: Reactive lymphadenopathy - infections in head/neck/congenital cysts

Young adults: Inflammation/infection - Viral/bacterial adenitis, Thyroid cancer

>40s : Malignant until proven otherwise



Refer

- Refer to GP when:

- Symptoms of Cx radiiculopathy persists/not improved with conservative management within 4 weeks - Clinical Evidence
- Incapacitating Neck/Arm Pain

Injury Mechanisms

- CT best for fractures, MRI better for soft tissue damage - F# commonly @ C1-2, C5-7 & T12-L2
- Four types of Spinal F#/Dislocation 1. Compression 2. Burst 3. Seat Belt Injuries 4. Fracture- Dislocation
- Compression:** Hyperflexion + Axial Compression - usually posterior height is maintained
- Burst Fractures** Axial loading of the spine
- Seat-Belt** Rapid Deceleration - Axis, middle + posterior structures affected

Investigations

Canadian C-Spine Rules

For Alert (GCS = 15) pts over 16 after trauma

- High Risk Factor** - >65 yo or Dangerous Mechanism of injury/Paresthesia in Extremities
- Low Risk Factor - allows safe assessment of ROM**
 - Simple Rear End Collision
 - Sitting Position in Emergency Department
 - Walking at any time
 - Delayed onset of Neck Pain
 - Absence of Midline Cx tenderness

Are they able to turn their heads Left and Right 45 degrees

N/A for <16, GCS <15, Acute Paralysis, Known Vertebral Disease/ previous surgery

Dangerous Mechanism of Injury = Fall from elevation >3 ft/five stairs, axial load to head, high speed vehicle accidents (>100km/h), rollover, ejected vehicles, bicycle/collisions



By **Siffi** (Siffi)
cheatography.com/siffi/
ko-fi.com/siffi7625

Not published yet.
 Last updated 14th November, 2021.
 Page 3 of 7.

Sponsored by **Crossw**
 Learn to solve cryptic c
<http://crosswordcheats>

Features in the history

Location	- Localised/Radiating - Localised = Muscle strain, ligament sprains, manipulable lesions, facet joint/disc degeneration - Radiation
Characteristics of pain	Sharp (acute) Dull/aching (Chronic) = Muscle/ligament/disc Deep/Boring pain = Bone/joint Electrical, numbing, tingling, shooting = neurogenic
Onset	Trauma? Anything that set it off? Life/Activity changes prior to the onset?
Aggravating & Relieving Factors	Pain during neck extension - compression of posterior elements - Usually the Facet Joints, consider NR if p - Pain with overhead Activities Consider TOS - Pain at the end of the day = chronic overuse, mechanical disorder, degeneration
Pain duration	Muscle strains = Recover in a few days to a couple of weeks Ligament Sprains = Up to a couple of months Disc Injuries/herniation = 3-6 months Chronic Pain = >6 months - degenerative, mechanical instability, chronic inflammatory/neuropathic process
Associated symptoms	Arm symptoms (pain, paraesthesia, weakness, clumsiness) Headaches, dizziness, nausea Difficulty Walking - scuffing of toes, feeling unbalanced (CSM) - Did they come on the same time as your complaint?



Red Flags

Condition	Red Flags
F#	Trauma, Loss of consciousness, Thrown from a vehicle, inability to move neck due to pain, Rust's sign, use of high dose
Tumour	>50 yo, Pain at rest, Unexplained weight loss, Hx of cancer, Failure to improve with previous treatments, Dysphagia, He Percussion
Infection	Systemic S&S, Risk factors (immunosuppression, underlying disease, penetrating wound, exposure to infectious disease at rest, Nuchal rigidity, Pain on Percussion
Spinal Cord Compression	Trauma to the neck, Paraesthesias of upper and or lower extremities, Difficulty walking/stiff gait, Babinski + Hoffman +v Clonus
Cerebral/Spinal Haemorrhage	Cerebrovascular symptoms/signs, Anticoagulant Use
Vertebral/Carotid Aneurysm	Cardiovascular Risk Factors, TIA

Neck Pain in Children

Consider: Infection, inflammation of cx lymphnodes - tonsillitis/pharyngitis. Meningitis, acute torticollis - Chronic Juvenile Arthritis

Neck Pain in the Elderly

Consider:

- Cx spondylosis with radiculopathy/myelopathy
- Atlantoaxial Subluxation - RA
- PMR
- Metastatic Cancer
- Pancoast Tumour
- Angina/MI
- Pharyngeal & Retropharyngeal infection/tumour



By **Siffi (Siffi)**
cheatography.com/siffi/
ko-fi.com/siffi7625

Not published yet.
 Last updated 14th November, 2021.
 Page 5 of 7.

Sponsored by **Crossw**
 Learn to solve cryptic c
<http://crosswordcheats>

Lumps Where?

Midline: Thyroid swellings, Thyroglossal cyst, Submental lymph nodes

Lateral (anterior triangle): Thyroid swellings, Submandibular gland swelling, Lymph nodes, Parotid swellings

Lateral (posterior) : Lymph nodes, Carotid artery aneurysm, Cx ribs

Neck Lumps

Congenital	Dermoid cysts	Thyroglossal cysts		
Developmental	Branchial cysts	Pharyngeal pouch		
Skin and subcutaneous tissue	Sebaceous cyst <i>ganglion</i> <i>can't remove if infected</i>	Lipoma <i>fatty lump</i>		
Thyroid	Goitre	Malignancy	Thyroiditis	
Salivary gland	Infection eg mumps <i>can't remove</i>	Ductal stone	Malignancy	
Lymph nodes	Infection	Malignancy (primary or secondary)		

Exam

Site, Size, Shape, Surface (4 S's)

Consistency, Colour, Compressible/fluctuant (3 C's)

Transillumination, Tenderness, Tethered (3 T's)

Autoimmune

Diabetes

RA

Pernicious Anaemia

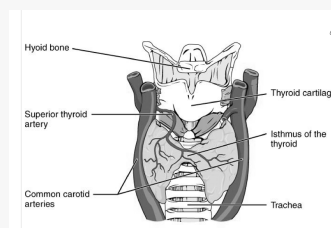
Hashimotos

MS

SLE

Vitiligo

Thyroid Anatomy



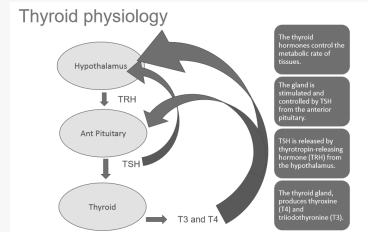
C

By **Siffi** (Siffi)
cheatography.com/siffi/
ko-fi.com/siffi7625

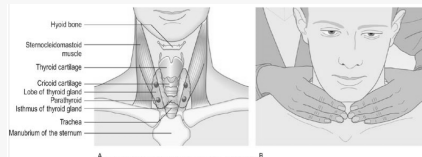
Not published yet.
 Last updated 14th November, 2021.
 Page 6 of 7.

Sponsored by **Crossw**
 Learn to solve cryptic c
<http://crosswordcheats>

Thyroid Physiology



Palpating the thyroid



Hypothyroidism

- If goitre = Hashimoto's, if no goitre = Atrophic primary hypothyroidism

- **Caused by:** Hashimoto's, Surgery/radioactive treatment to the thyroid, Side effect of medications (Amiodarone, Lithium), Iodine deficiency, Pituitary

Symptoms: Tiredness, Lethargy, Xanthomas, Constipation, Intolerance to cold, Muscle stiffness, Cramps, CTS, Menorrhagia, Slowing of intellectual activity, decreased appetite, weight gain, Dry skin + hair loss, Deep, hoarse voice

Signs: Expressionless, dull face with periorbital + tongue swelling, Sparse hair, Pale cool skin with rough, doughy texture, Coarse dry brittle hair, G Prolonged relaxation phase of DTR, Peripheral neuropathy

- Thyroxine

Hyperthyroidism

- Grave's disease

Symptoms: Restless, nervous, emotional irritable, sleeping poorly, Tremor of the hands, Losing weight, Palpitations, Sweating and dislike of heat changes (light/infrequent), Skin problems - hair thinning, itching. Increased thirst, Tiredness + muscle weakness

Signs: Sinus Tachycardia (can be atrial fib), Fine tremor, Warm, moist skin, Goitre, Hyperreflexia, Proximal Myopathy, muscle weakness and weight loss

- **Medication:** Beta blockers, Carbimazole, Surgery: Thyroidectomy, Radio Iodine (kills iodine producing cells)

Exam: Observe + Palpate Thyroid gland with two hands standing behind the patient, get patient to swallow **Normally, gland is not palpable unless**

