

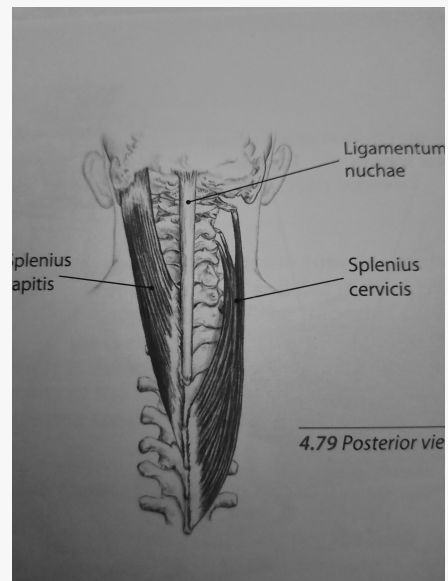


By **Siffi (Siffi)**
cheatography.com/siffi/

Not published yet.
Last updated 16th January, 2021.
Page 1 of 100.

Sponsored by **Readable.com**
Measure your website readability!
<https://readable.com>

Splenius Capitus



Origin: Mastoid process

Insertion: Tips of the SP of 7th Cx vertebra

Nerve: Lateral branches of the second and third Cx dorsal Rami

Action: Ipsilateral rotation - bilaterally extends the head

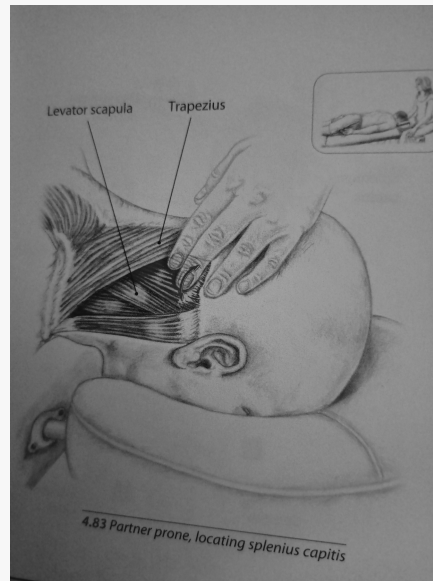


By **Siffi** (Siffi)
cheatography.com/siffi/

Not published yet.
Last updated 16th January, 2021.
Page 2 of 100.

Sponsored by **Readable.com**
Measure your website readability!
<https://readable.com>

Splenius Capitis - Palpation



- Get patient to extend head slightly to locate border of the traps
- Just lateral to the border of the traps lies Splenius Cap
- Get pt to rotate head towards side of palpation - muscle should contract

C

By **Siffi (Siffi)**
cheatography.com/siffi/

Not published yet.
Last updated 16th January, 2021.
Page 3 of 100.

Sponsored by **Readable.com**
Measure your website readability!
<https://readable.com>

Trps



- Causes Headaches
- Associated with C2 manipulable lesions

C

By **Siffi (Siffi)**
cheatography.com/siffi/

Not published yet.
Last updated 16th January, 2021.
Page 4 of 100.

Sponsored by **Readable.com**
Measure your website readability!
<https://readable.com>

Splenius Cervicis

Origin: TVPs of atlas and TVPs of the axis and posterior tubercle of the third cx vertebrae

C

By **Siffi** (Siffi)
cheatography.com/siffi/

Not published yet.
Last updated 16th January, 2021.
Page 5 of 100.

Sponsored by **Readable.com**
Measure your website readability!
<https://readable.com>

Splenius Cervicis (cont)

Insertion: 3rd-6th Tx SP

C

By **Siffi** (Siffi)
cheatography.com/siffi/

Not published yet.
Last updated 16th January, 2021.
Page 6 of 100.

Sponsored by **Readable.com**
Measure your website readability!
<https://readable.com>

Splenius Cervicis (cont)

Nerve: Lateral Branches of the lower cx dorsal rami

C

By **Siffi** (Siffi)
cheatography.com/siffi/

Not published yet.
Last updated 16th January, 2021.
Page 7 of 100.

Sponsored by **Readable.com**
Measure your website readability!
<https://readable.com>

Splenius Cervicis (cont)

Action: Ipsilateral rotation of upper cx spine - bilaterally extends upper cx

- Cervix = neck (Latin)



By **Siffi** (Siffi)
cheatography.com/siffi/

Not published yet.
Last updated 16th January, 2021.
Page 8 of 100.

Sponsored by **Readable.com**
Measure your website readability!
<https://readable.com>

Trps



- Main muscle affected in Whiplash (Along with SCM)
- Causes Headaches

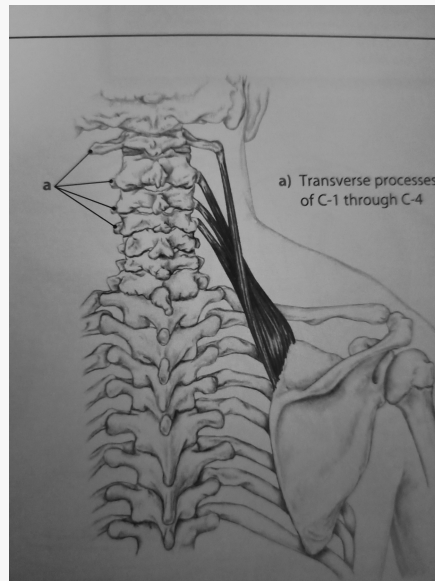
C

By **Siffi (Siffi)**
cheatography.com/siffi/

Not published yet.
Last updated 16th January, 2021.
Page 9 of 100.

Sponsored by **Readable.com**
Measure your website readability!
<https://readable.com>

Levator Scapulae



Origin: TVPs of the atlas and axis + Posterior tubercles of the TVP of the 3rd and 4th cx

Insertion: Medial end of scapular spine

Nerve: Branches of 3rd and 4th Cx spine nerves + 5th Cx nerve - Dorsal Scapular Nerve

Action: Rotation of the scapula - depresses shoulder Ipsilateral + lateral flexion of the cx

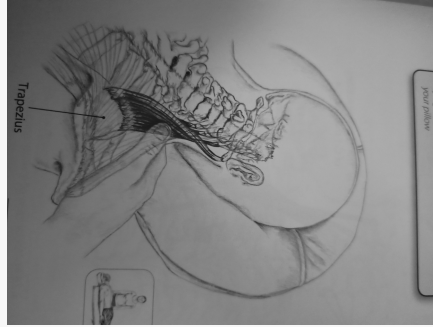


By **Siffi (Siffi)**
cheatography.com/siffi/

Not published yet.
Last updated 16th January, 2021.
Page 10 of 100.

Sponsored by **Readable.com**
Measure your website readability!
<https://readable.com>

LS - Palpation



- Just off superior angle of the scapula
- Should feel ropy, deep to the traps

C

By **Siffi** (Siffi)
cheatography.com/siffi/

Not published yet.
Last updated 16th January, 2021.
Page 11 of 100.

Sponsored by **Readable.com**
Measure your website readability!
<https://readable.com>

Trps



C

By **Siffi (Siffi)**
cheatography.com/siffi/

Not published yet.
Last updated 16th January, 2021.
Page 12 of 100.

Sponsored by **Readable.com**
Measure your website readability!
<https://readable.com>

Suboccipitals

Rectus Capitis Posterior Major:

Origin: Spine of the axis

Insertion: Lateral part of inferior nuchal line and the occipital bone



By **Siffi (Siffi)**
cheatography.com/siffi/

Not published yet.
Last updated 16th January, 2021.
Page 13 of 100.

Sponsored by **Readable.com**
Measure your website readability!
<https://readable.com>

Suboccipitals (cont)

Rectus Capitis Posterior Minor:

Origin: Tubercle on the posterior arch of the atlas

Insertion: Medial part of inferior nuchal line and occipital bone - Can be attached to the posterior atlanto-occipital membrane



By **Siffi (Siffi)**
cheatography.com/siffi/

Not published yet.
Last updated 16th January, 2021.
Page 14 of 100.

Sponsored by **Readable.com**
Measure your website readability!
<https://readable.com>

Suboccipitals (cont)

Obliquus Capitis Inferior:

Origin: Lateral surface of the spine + adjacent upper part of the lamina

Insertion: Inferoposterior aspect of the TVP of the atlas



By **Siffi (Siffi)**
cheatography.com/siffi/

Not published yet.
Last updated 16th January, 2021.
Page 15 of 100.

Sponsored by **Readable.com**
Measure your website readability!
<https://readable.com>

Suboccipitals (cont)

Obliquus Capitis Superior:

Origin: Upper surfaces of the TVP of the atlas

Insertion: Occipital bone



By **Siffi (Siffi)**
cheatography.com/siffi/

Not published yet.
Last updated 16th January, 2021.
Page 16 of 100.

Sponsored by **Readable.com**
Measure your website readability!
<https://readable.com>

Suboccipitals (cont)

Nerve: Dorsal ramus of the 1st Cx nerve

C

By **Siffi** (Siffi)
cheatography.com/siffi/

Not published yet.
Last updated 16th January, 2021.
Page 17 of 100.

Sponsored by **Readable.com**
Measure your website readability!
<https://readable.com>

Suboccipitals (cont)

Action: Extension and ipsilateral rotation of the head



By **Siffi** (Siffi)
cheatography.com/siffi/

Not published yet.
Last updated 16th January, 2021.
Page 18 of 100.

Sponsored by **Readable.com**
Measure your website readability!
<https://readable.com>

Suboccipitals



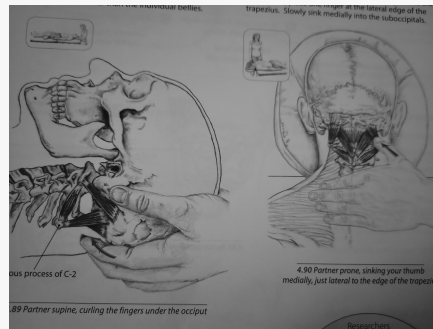
C

By **Siffi (Siffi)**
cheatography.com/siffi/

Not published yet.
Last updated 16th January, 2021.
Page 19 of 100.

Sponsored by **Readable.com**
Measure your website readability!
<https://readable.com>

Suboccipitals - Palpation



C

By **Siffi (Siffi)**
cheatography.com/siffi/

Not published yet.
Last updated 16th January, 2021.
Page 20 of 100.

Sponsored by **Readable.com**
Measure your website readability!
<https://readable.com>

Trps



By **Siffi** (Siffi)
cheatography.com/siffi/

Not published yet.
Last updated 16th January, 2021.
Page 21 of 100.

Sponsored by **Readable.com**
Measure your website readability!
<https://readable.com>

Semispinalis Capitis

Origin: Medial part of the area between superior and inferior nuchal lines of the occipital bones

C

By **Siffi** (Siffi)
cheatography.com/siffi/

Not published yet.
Last updated 16th January, 2021.
Page 22 of 100.

Sponsored by **Readable.com**
Measure your website readability!
<https://readable.com>

Semispinalis Capitis (cont)

Insertion: Superior articular Processes of the lower 4 Cx Vb + Tips of the TVPs of the upper 6 or 7 Tx

C

By **Siffi** (Siffi)
cheatography.com/siffi/

Not published yet.
Last updated 16th January, 2021.
Page 23 of 100.

Sponsored by **Readable.com**
Measure your website readability!
<https://readable.com>

Semispinalis Capitis (cont)

Nerve: Descending branches of the greater occipital nerve C2 + third Cx nerve C3

C

By **Siffi** (Siffi)
cheatography.com/siffi/

Not published yet.
Last updated 16th January, 2021.
Page 24 of 100.

Sponsored by **Readable.com**
Measure your website readability!
<https://readable.com>

Semispinalis Capitis (cont)

Action: Extension of the head

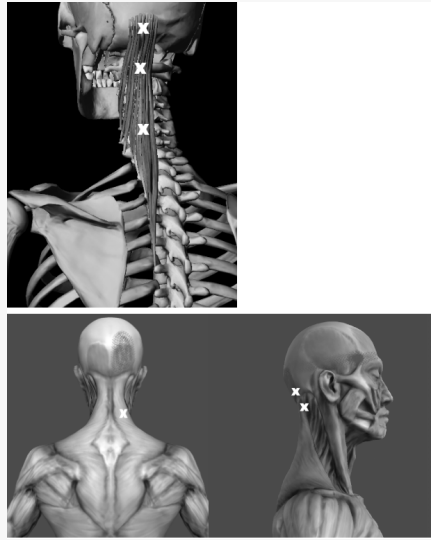
C

By **Siffi (Siffi)**
cheatography.com/siffi/

Not published yet.
Last updated 16th January, 2021.
Page 25 of 100.

Sponsored by **Readable.com**
Measure your website readability!
<https://readable.com>

Trps



Can Trap the Greater Occipital Nerve when hypertonic

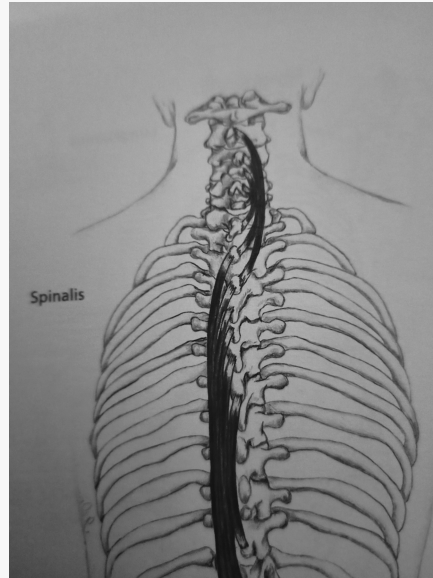


By **Siffi (Siffi)**
cheatography.com/siffi/

Not published yet.
Last updated 16th January, 2021.
Page 26 of 100.

Sponsored by **Readable.com**
Measure your website readability!
<https://readable.com>

Semispinalis Cervicis



Origin: SP of 2-5th Cx VB

Insertion: Upper five/six Tx TVP

Nerve: Medial branches of the dorsal rami of adjacent spinal nerves

Action: Extension of the neck

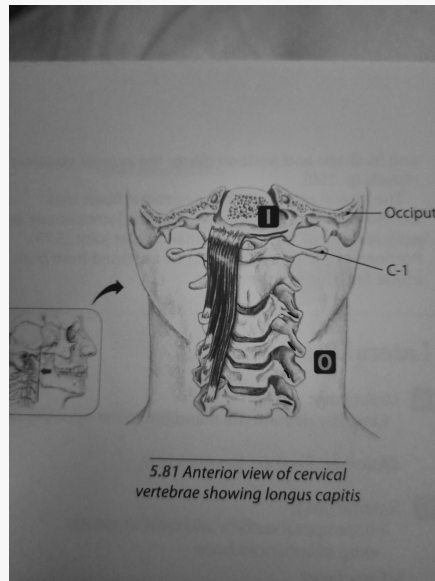
C

By **Siffi** (Siffi)
cheatography.com/siffi/

Not published yet.
Last updated 16th January, 2021.
Page 27 of 100.

Sponsored by **Readable.com**
Measure your website readability!
<https://readable.com>

Longus Capitis



Origin: Posterior Edge of the mastoid process

Insertion: TVPs of lower 3 or 4 cx and upper 4 Tx

Nerve: Segmental Supply from the lateral branches of the dorsi rami

Action: Stabilisation/proprioceptive role



By **Siffi (Siffi)**
cheatography.com/siffi/

Not published yet.
Last updated 16th January, 2021.
Page 28 of 100.

Sponsored by **Readable.com**
Measure your website readability!
<https://readable.com>

Trp

- Below and Behind the ear + periorbital region

C

By **Siffi (Siffi)**
cheatography.com/siffi/

Not published yet.
Last updated 16th January, 2021.
Page 29 of 100.

Sponsored by **Readable.com**
Measure your website readability!
<https://readable.com>

Sternocleidomastoid (SCM)

Origin:

Medial: Upper part of the anterior surface of the manubrium and sterni

Lateral head: Superior surface of the medial third of clavicle



By **Siffi (Siffi)**
cheatography.com/siffi/

Not published yet.
Last updated 16th January, 2021.
Page 30 of 100.

Sponsored by **Readable.com**
Measure your website readability!
<https://readable.com>

Sternocleidomastoid (SCM) (cont)

Insertion: Lateral surface of mastoid process

C

By **Siffi** (Siffi)
cheatography.com/siffi/

Not published yet.
Last updated 16th January, 2021.
Page 31 of 100.

Sponsored by **Readable.com**
Measure your website readability!
<https://readable.com>

Sternocleidomastoid (SCM) (cont)

Nerve: Spinal part of accessory nerve, branches from the ventral rami of 2nd, 3rd and sometimes 4th Cx nerves

C

By **Siffi (Siffi)**
cheatography.com/siffi/

Not published yet.
Last updated 16th January, 2021.
Page 32 of 100.

Sponsored by **Readable.com**
Measure your website readability!
<https://readable.com>

Sternocleidomastoid (SCM) (cont)

Action: Tilts head towards ipsilateral shoulder, rotates the head (turns the face to the opposite side). From below, SCM draws the head forwards and raises head when the body is supine. When head is fixed, SCM helps elevates the tx in forced inspiration

- Torticollis



By **Siffi (Siffi)**
cheatography.com/siffi/

Not published yet.
Last updated 16th January, 2021.
Page 33 of 100.

Sponsored by **Readable.com**
Measure your website readability!
<https://readable.com>

Trp



- Important for Whiplash
- A big cause of myogenic headaches

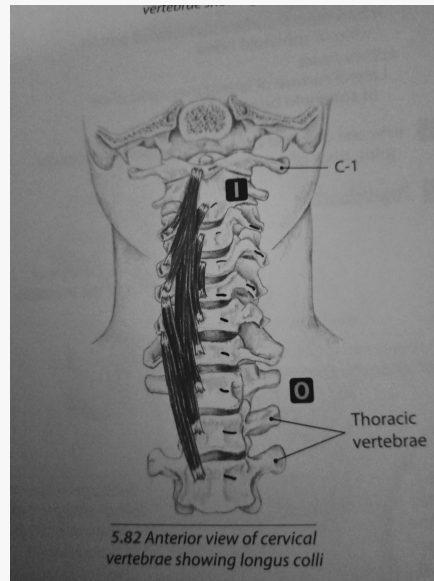
C

By **Siffi (Siffi)**
cheatography.com/siffi/

Not published yet.
Last updated 16th January, 2021.
Page 34 of 100.

Sponsored by **Readable.com**
Measure your website readability!
<https://readable.com>

Longus Colli



C

By **Siffi** (Siffi)
cheatography.com/siffi/

Not published yet.
Last updated 16th January, 2021.
Page 35 of 100.

Sponsored by **Readable.com**
Measure your website readability!
<https://readable.com>

Longus Colis

Origin: Anterior surface of the vertebral column between 2nd and 3rd Tx

Inferior oblique: Front of the Vb of the first two or three Tx vertebra **Insertion:** Anterior tubercles of the TVPs of the 5th and 6th Cx

Superior Oblique: Anterior tubercles of the TVPs of the 3rd, 4th, 5th Cx vertebral **Insertion:** Anterolateral surface of the tubercle on the anterior arch of the atlas.

Vertical Intermediate: Fronts of the bodies of the upper three tx and lower three Cx vertebrae **Insertion:** Fronts of the bodies of the second, third and fourth Cx VB

C

By **Siffi** (Siffi)
cheatography.com/siffi/

Not published yet.
Last updated 16th January, 2021.
Page 36 of 100.

Sponsored by **Readable.com**
Measure your website readability!
<https://readable.com>

Longus Colis (cont)

Nerve: Branches from the ventral rami of the second, third, fourth, fifth and sixth Cx spinal nerves

C

By **Siffi (Siffi)**
cheatography.com/siffi/

Not published yet.
Last updated 16th January, 2021.
Page 37 of 100.

Sponsored by **Readable.com**
Measure your website readability!
<https://readable.com>

Longus Colis (cont)

Action: Flexion and assists in lateral flexion

- Also affected in whiplash (rear end)

- Can be affected by calcific tendinitis - neck pain, stiffness, dysphagia and odynophagia (MRI/CT needed) - Treated by NSAIDs

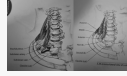


By **Siffi** (Siffi)
cheatography.com/siffi/

Not published yet.
Last updated 16th January, 2021.
Page 38 of 100.

Sponsored by **Readable.com**
Measure your website readability!
<https://readable.com>

Scalanes



C

By **Siffi (Siffi)**
cheatography.com/siffi/

Not published yet.
Last updated 16th January, 2021.
Page 39 of 100.

Sponsored by **Readable.com**
Measure your website readability!
<https://readable.com>

Scalenes

Scalenus Anterior:

Origin: Anterior tubercles of the TVP of the 3-6th Cx

Insertion: Scalene Tubercle on the inner border of the First rib + ridge on the upper surface of the rib, anterior to the groove for the subclavian artery

Nerve: Branches of the Ventral Rami of the 4-6th Cx spinal nerves

Action: Lateral Flexion of the cx and elevation of first rib - respiration

C

By **Siffi (Siffi)**
cheatography.com/siffi/

Not published yet.
Last updated 16th January, 2021.
Page 40 of 100.

Sponsored by **Readable.com**
Measure your website readability!
<https://readable.com>

Scalenes (cont)

Scalenus Medius:

Origin: Above the TVP of the axis and front of the posterior tubercles of the TVP of the lower 5 Cx, extends to the TVP of the atlas.

Insertion: Upper surface of the first rib

Nerve: Branches of the ventral rami of the 3-8th Cx spinal nerves

Action: Lateral flexion of the Cx and elevation of the first rib - respiration



By **Siffi** (Siffi)
cheatography.com/siffi/

Not published yet.
Last updated 16th January, 2021.
Page 41 of 100.

Sponsored by **Readable.com**
Measure your website readability!
<https://readable.com>

Scalenes (cont)

Scalenus Posterior:

Origin: Posterior tubercles of the TVP of the 4-6th Cx

Insertion: Outer surface of the second rib

Nerve: Branches of the ventral rami of 6-8th Cx spinal nerves

Action: Lateral Flexion of the cx and elevation of the 2nd rib - respiration

- Skalenos (Greek) = uneven
- A 4th Scalene can be present (Sibson's muscle) located behind lower portion of anterior scalene
- Brachial Plexu and subclavian artery pass through anterior and middle scalene (TOS)
- Subclavian vein and phrenic nerve pass anteriorly to the anterior scalene




By **Siffi** (Siffi)
cheatography.com/siffi/

Not published yet.
Last updated 16th January, 2021.
Page 42 of 100.

Sponsored by **Readable.com**
Measure your website readability!
<https://readable.com>

Scalenes - Palpation



C

By **Siffi (Siffi)**
cheatography.com/siffi/

Not published yet.
Last updated 16th January, 2021.
Page 43 of 100.

Sponsored by **Readable.com**
Measure your website readability!
<https://readable.com>

Trps



- Rotation of head fully to side of pain + pull chin down - aggravates Trps in scalenes
- Scalenes Trps cannot cause headaches
- Mimics a disc herniation
- Can be extremely painful - often causes a sympathetic response

C

By **Siffi (Siffi)**
cheatography.com/siffi/

Not published yet.
Last updated 16th January, 2021.
Page 44 of 100.

Sponsored by **Readable.com**
Measure your website readability!
<https://readable.com>