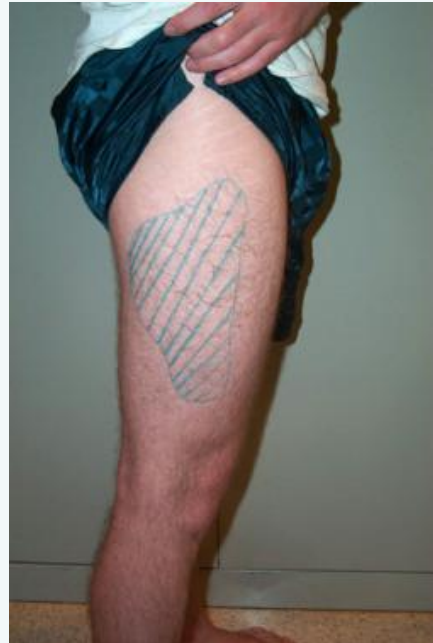


Meralgia Paresthetica



- Picture shows affected area in this condition - burning pain and paresthesia
- Pts complain of "feels like someone is placing a tennis racquet on my leg"
- Lateral femoral cutaneous (L2 & L3) nerve affected (entrapment beneath inguinal ligament or sartorius/TFL)

Demographics/Risk factors

- Occurs at any age - most often affects middle aged adults
- Diabetics
- Can be bilateral
- Can be either side if unilateral
- Men more than women (work - carpentry tool belts, police duty belts, soldier body armour)
- Excessive compression/ischemic stretch
- Tight clothing
- Pregnancy
- Obesity (>30 BMI)
- Seatbelt compression
- Excessive prone lying on hard surface
- Athletes (gymnastics, baseball, soccer, bodybuilding, strenuous exercise)
- Excessive anterior pelvic tilt , Leg length inequality



Presentation

- Middle aged patient with >1 of risk factors
- Isolated pain/paraesthesia/hypersensitivity on outside of thigh
- Dull, aching, itching, buzzing, burning
- Can impair sleep + ADLs
- Aggravated by walking , hip/lx ext
- Relieved by sitting (decreases tension on inguinal ligament)
- **Screen for diabetes (family hx, hypertension, age, gender, ethnicity, physical activity level, SOB, BMI frequent thirst, pulses, vibration sensation)**
- TTP over lateral inguinal ligament (1 - 2 finger widths inferior and medial to ASIS)
- +ve Yeomans, +ve Tinels , +ve NTT of LFCN
- Assess for hypertonic iliopsoas, TFL, Sartorius
- Assess for joint dysfunction of Lx, SI, hip
- Assess for lower crossed, leg length inequality, paradoxical breathing
- Neurological exam - numbness/hyperesthesia over distribution of LFCN (above picture)
- **If motor/reflex signs present, consider other diagnosis - disc/radiculopathy** - LFCN is a purely sensory nerve

Imaging

- Not usually required (well defined)
- Nerve conduction study gold standard
- MRI if mass/lesion in retroperitoneal space/lx radiculopathy

DDx

- Lx radiculopathy
- Trigger point referral (glut medius/TFL)
- Retroperitoneal, abdominal, pelvic pathology
- Lx disc lesion
- Diabetes



Management

- Highly successful (>90%)
- Advise patient to wear looser clothing
- Rest from aggravating activity (repetitive hip flexion)
- Loosing weight
- Carrying a toolbox instead of a belt
- Not wearing high heels (causes excessive anterior pelvic tilt)
- Myofascial release/stretching of hip flexors, sartorius, TFL, Quads, thigh adductors
- Nerve mobilisation
- Stabilisation of core and pelvis
- Ice and NSAIDs
- Severe cases - anesthetic block/steroid injection
- If not better, surgical decompression is indicated

C

By **Siffi (Siffi)**
cheatography.com/siffi/

Not published yet.
Last updated 3rd February, 2021.
Page 3 of 3.

Sponsored by **Readable.com**
Measure your website readability!
<https://readable.com>