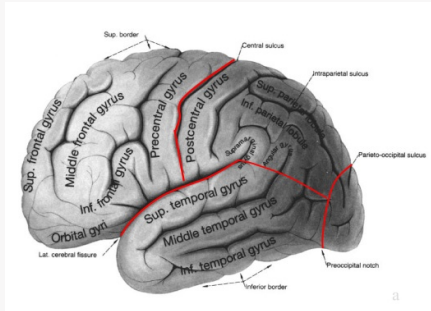


Lobes of the brain



Types of Intracranial disorders

Cerebrovascular damage	Haemorrhage
	Infarction
	Aneurysms
	Blood disorders
	Arteriovenous Malformations
Haematomas	Intradural
	Extradural
Intracranial Tumours	Benign
	Malignant
Intracranial infection	Abscess
Post trauma	Concussion

Tumours

Supratentorial Tumours	Infratentorial Tumours
Raised ICP + brain shift S&S	Raised ICP + brain shift S&S
Tentorial herniation then tonsillar herniation	S&S of CSF outflow blockage
	Causes tonsillar herniation
	VI Nerve Palsy - BS pushed downwards, stretches VI nerve over petrous tip Unreliable sign

Extradural haematoma:

Pushes on hemisphere sideways under Falx, downwards through tentorium
 Stretches CN III over edge of the tentorium - unilateral III nerve palsy **reliable sign**

Occipital Lobe Functional areas

Visual Association areas	Main Visual cortex
Calcarine fissure (medially in right hemisphere)	

Occipital Lobe Lesions

Seizures with flashing light Aura	Visual Field Defects
Dyslexia	Visual Agnosia (cannot recognise visual information)

Parietal lobe Lesions (EITHER)

Sensory Seizures	Soft Motor signs
Visual pathway Disturbance	Postural Sensation disturbed
Decreased Passive Joint Movement Sense	Touch Localisation Disturbed
2 pt Discrimination disturbed	Appreciation of size + texture Disturbed
Perceptual Rivalry	Altered Optokinetic nystagmus

Perceptual Rivalry: When presented with two images, instead of them being superimposed, the images appear separately
Optokinetic nystagmus: Following an object when stationary (larger visual field, oculomotor response and directs image onto the retina, compared to small moving visual objects, directs image onto fovea in smooth pursuit)

Parietal Lobe Lesions (RIGHT & LEFT)

RIGHT	LEFT
Anosognosia - no longer aware of opposite side	Confusion of right and left limb
Dyspraxia - loss of acquired skills	Finger agnosia
Disturbance of Geographic Memory	Acalculia
	Agraphia
	Wernicke's dysphagia

Wernicke's dysphagia- loss of production/comprehension of spoken &/or written language (acquired)



Frontal Lobe

Functional areas:

Olfactory Bulb, tract + optic nerve	Frontal Poles
Cingulate Gyrus	Frontal eye fields
Cortical control of micturition (urination)	Corpus Callosum
Motor cortexes	Rolandic fissure (fissure between occipital + frontal lobe)
Sylvian Fissure (fissure between temporal + frontal lobe)	Broca's area

Frontal lobe Lesions:

Loss of drive
Apathy
Decreasing concern about personal appearance, hygiene, family affairs, business
Memory problems
Diminished intellect
Epilepsy Focal, motor
Adversive (includes eyes)
Status Epilepticus (seizure lasting 10 minutes or more)
Possible Temporal lobe attacks due to its close proximity
Frontal lobe - personality, acquired social behaviour

More Symptoms

Weakness on opposite side of face and/body
If parasagittal, legs are affected bilaterally
Loss of micturition (urge incontinence)
Speech Disturbance - Dysphagia (Broca's)
Visual Disturbance - in visual and or acuity
Alteration in smell

Signs

Intellectual impairment
Memory Defect
+ve Grasp Reflex
Contralateral UMN signs
Unilateral anosmia
Visual pathway deficits
Dysphasic signs

Temporal Lobe functional areas:

Uncinate fasciculus (connects uncus to orbital frontal cortex)	Hippocampus
Uncus	Inferior longitudinal fasciculus (to visual association areas)
Motor fibres entering cerebral peduncles	

Temporal Lobe Lesions

Epileptic - complex partial seizures "on/off"

Complex Automisms :

Lipping	Sucking
Kissing	Repeated fiddling with clothing
Walking/driving then "waking up"	

Prodromes: Visual/auditory/smells/taste hallucinations

Unpleasant visceral sensations "Something awful is about to happen"

Deja vu Jamais vu

Deja vu: - described as a strong sensation that a current event has happened/occurred before

Jamais vu: - opposite to deja vu. Something that has happened in a person's life but they have the feeling it happened for the first time.

