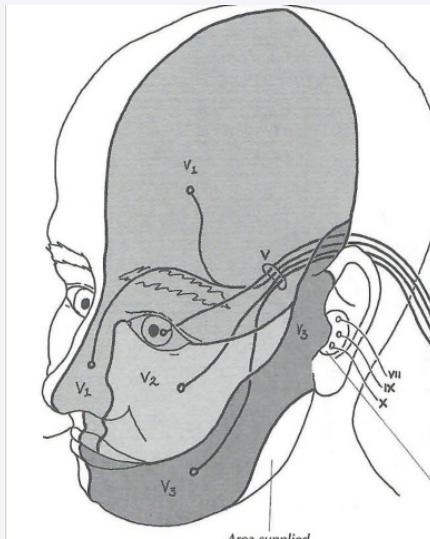


Sensation of V



Pattern of sensory loss -

1 division = peripheral nerve lesion

>1 division = Root/BS lesion

"onion skin" = BS lesion

Type of sensory loss

Dissociated sensory loss (pain + temperature affected, touch preserved) = BS lesion

Presence of limb motor &/or sensory signs? =

Yes + with cranial nerve palsies = intrinsic BS lesion

Yes + without CN palsies = supratentorial/upper cx lesion

Conditions

Vascular - ischaemia (dorsal/lateral area)

Neoplastic - benign/malignant

Demyelination - MS

Syringobulbia

Acoustic Neuroma

Trigeminal neuroma

Meningitis

Petrositis (inflammation of petrous part of temporal bone)- otitis media, osteitis/meningitis - VI affected too

Skull base Nasopharyngeal cancer/Mets

Cavernous sinus Involvement of IV, VI, + V1

- Tumour, intracavernous aneurysm, cavernous sinus thrombosis (oedema + pain in the eye +ICP), Tolosa Hunt syndrome

Conditions affecting VII

Bells Palsy: at stylomastoid foramen

Ramsay Hunt at geniculate ganglion

Hemifacial Spasm at exit from BS

Localising Concepts

Unilateral involvement of the lower face Contralateral supranuclear lesion (UMNL) - Vascular, Tumour, Demyelination, Infection

Unilateral involvement of the upper and lower face + contralateral eye closure Ipsilateral nuclear/infranuclear lesion

Peripheral Nerve Lesion

S&S

Unilateral weakness

Usually localised to specific muscle group

Causes

Parotid gland lesion

Parotid operations

Facial Trauma

Haematoma

Facial Canal

S&S

Unilateral, complete facial weakness

Loss of taste +salivation

Causes

F# of skull base

Spread of middle ear infection

Bell's palsy - most common

Leukaemic deposits

Internal Auditory Meatus

S&S

Ramsey Hunt Syndrome:

Vesicular rash on external ear

LMNL paralysis of facial nerve

Loss of taste sensation over anterior 2/3 of tongue

Causes

Herpes Zoster of CN VII + Chorda Tympani

Acoustic tumours/meningioma

S&S

V, VIII (IX, X, XI) palsy

Loss of taste, salivation & lacrimation

Hyperacusis



Wallenberg syndrome

S&S	Causes
Long tract signs	Dorsal BS lesion @ level of pons - Vascular/ischaemic in origin (PICA)
Ipsilateral LMNL to face	Demyelination
Ipsilateral VI palsy	MND
Ipsilateral loss of pain & Temp of face	Syringobulbia
Contralateral decrease in touch, position and vibration	Tumour
Contralateral decrease in pain and temperature in limbs	

C

By **Siffi (Siffi)**
cheatography.com/siffi/

Not published yet.
Last updated 7th May, 2021.
Page 3 of 3.

Sponsored by **Readable.com**
Measure your website readability!
<https://readable.com>