Information

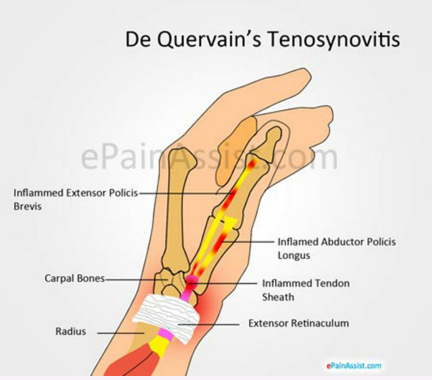

- Inflammation of tendons and synovial sheaths of APL and EPB

Causes

- Repetitive friction
- Microtrauma
- Lifting, grasping and pinching with wrist radial or ulnar deviation (causes tendons to rub against radial styloid process)
- Gardening, knitting, cooking, playing a musical instrument, carpentry, walking a pet, texting, video gaming, sports (golf, volleyball, fly fishing, racquet sports, excessive mobile use
- Lifting children/babies
- Diabetes
- RA
- Pregnancy (changes in oestrogen)
- Women more than men
- Black people affected more than other races
- Extra defect - intracompartmental septum

Presentation

- Pain lateral aspect of wrist but can move towards brachioradialis
- Pain may begin gradually/abruptly
- Pain aggravated by movements of the thumb/hand (forceful pinching/grasping/twisting)
- Swelling over EPB and APL tendons
- "Squeaking" sound with movement of the wrist
- Catching/snapping can occur
- Numbness over dorsal thumb and index finger
- Tenderness over first dorsal compartment (radial styloid process)
- Decreased ROM of thumb (resisted thumb extension painful)
- Diminished pinch grip (Determine from CTS)
- +ve Finkelsteins
- If intracompartmental septum +ve EPB entrapment test

Sponsored by **Readable.com**
Measure your website readability!
https://readable.com

Imaging

- Ultrasound
- MRI only if red flags are present (Hx of trauma, systemic signs, failed conservative care)

DDx

- Intersection syndrome
- OA of the 1st CMC
- Thumb sprain
- Ganglion cyst
- Distal radial nerve entrapment
- Cervical Radiculopathy

Management

- US
- Laser
- Cryotherapy
- NSAIDs
- Rest (avoid activities that provoke pain, take frequent breaks)
- Splinting?
- Stretching of APL, EPB, wrist flexors, extensors, brachioradialis
- Myofascial release of first dorsal compartment, wrist extensors, brachioradialis
- SMT of wrist, Cx

Poor prognosis factors: Pain score >8/10, involvement of sensory branch of the radial nerve, inability to tolerate NSAIDs, inability/unwillingness to perform home therapy and implement changes in ADLs, Severe swelling over 1st dorsal compartment, presence of intracompartmental septum

- Surgery if conservative treatment or injection fails

Sponsored by **Readable.com**
Measure your website readability!
https://readable.com