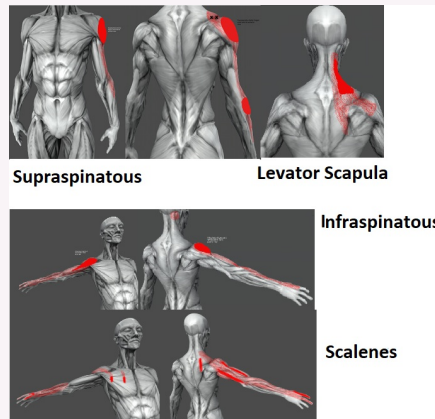


TrP pain referral similar to cx radiculopathy



- Supraspinatous - C5
- Infraspinatous - C5-7
- Scalenus Anterior - C5-C7
- Levator Scapulae C8,T1

Cx Disc Herniation

- More likely to occur posterolaterally
- Hard Disc Derangement = older patient with degenerative changes
- Soft Disc Derangement = young pts, trauma commonly benign
- Look out for C8,T1 lesions , disc herniations are rare - could be non-mechanical

NR Symptoms

Root	Symptoms
C5	Pain lateral upper arm to elbow, medial scapula border
C6	Pain in the lateral forearm, thumb and index finger
C7	Neck pain, medial scapula down to middle finger
C8	Neck pain, radiating to the shoulder, ulnar side of forearm and little finger
T1	Pain in shoulder and axilla to olecrana

Hx Findings

- Sharp, Aching pain in neck radiating into arm
- Sensory Changes in dermatonal fashion , tingling, numbness, loss of sensation
- Bakody's sign (abducting the shoulder and placing hand on their head) reduces symptoms
- Coughing, Sneezing/straining (Valsalva) worsens pain
- Stiffness of neck with decreased ROM
- Myotomal weakness in muscles supplied by effected nerve root
- Pain may wake up patient at night (common in neurological pain)



Exam Findings

- Pt head tilts away from side of radicular pain	- AROM reduced in Extension, rotation and lateral flexion - flexion relieves pain
- Tenderness of paraspinal cx muscles, Trps in muscles supplied by the affected nerve	-Cx spine compression & Doorbells +ve, Cx distraction relieves pain
- SMR affected (Diminished & Asymmetrical)	- Gait, LL reflexes & Hoffmans and Babsinki for suspected myelopathy

Cervical Spine Injuries

Fracture

Dislocations

Spondylolisthesis

Disc Derangements



By **Siffi (Siffi)**
cheatography.com/siffi/

Not published yet.
Last updated 4th January, 2021.
Page 2 of 2.

Sponsored by **Readable.com**
Measure your website readability!
<https://readable.com>