

Causes

- Fall onto lateral shoulder
- FOOSA
- Direct blow

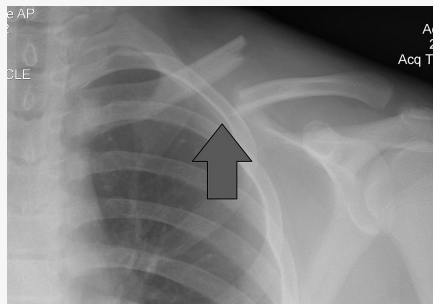
Classification

- **Group 1:** fractures involving middle 1/3 of clavicle (most common- not displaced)
- Group 2:** Fracture of distal 1/3 of clavicle (direct blow to shoulder - medial fragment has marked displacement in a cephalad direction, caudal displacement of distal fragment)
- Group 3:** Medial 1/3 of clavicle (uncommon - strong force to the anterior chest - high risk of neurovascular/intrathoracic injury)

Presentation

- Hx of trauma
- Patient cradles affected arm
- Affected shoulder usually slumped anteriorly and inferiorly
- Pain intensifies with movement
- On observation, swelling, ecchymosis
- Palpation shows tenderness over lesion
- Gentle movement produces crepitus of the ends
- Assessment of lung sounds, distal pulses, observe for vascular problems in upper extremity (swelling, discolouration)

Imaging



- May appear normal on x-ray if non-displaced
- Repeat x-ray 7-10 days after injury or CT
- US



Management

- Rest and protection of non-displaced clavicle
- Ice and analgesics
- Arm sling
- Begin elbow ROM exercises as pain decreases
- When f# heals, begin shoulder mobility/strength training (usually 6-8 weeks)
- Surgical referral if group 2 and 3 fractures, multiple fractures, fractures with interposed muscle, evidence of neurovascular compromise, inability to tolerate conservative management
- Good outcomes with both surgery and conservative care

C

By **Siffi** (Siffi)
cheatography.com/siffi/

Not published yet.
Last updated 5th January, 2021.
Page 2 of 2.

Sponsored by **CrosswordCheats.com**
Learn to solve cryptic crosswords!
<http://crosswordcheats.com>