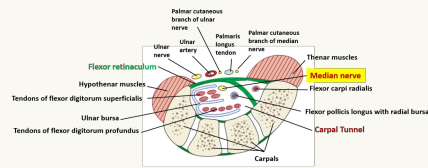


### Anatomy



- Tendons of FDS, FDP, median nerve, FPL pass under the flexor retinaculum
- Palmar cutaneous branch of ulnar, PL tendon, ulnar artery and nerve and palmar cutaneous branch of median nerve pass over the carpal tunnel

### Demographics

Most common nerve entrapment

- Females more likely to be affected than males
- More prevalent in white adults
- More common in dominant hand
- Rare in developing countries (work is not as repetitive)

### Risk Factors

- Prolonged wrist flexion/extension
- Repetitive wrist movements
- Exposure to vibration/cold
- Diabetes
- Hypothyroidism
- RA
- Increased BMI
- Renal disease
- Thicken transverse ligament
- Short stature
- Trauma
- OA
- Pregnancy
- CONSIDER ISCHEMIA (CAD)



By **Siffi (Siffi)**  
[cheatography.com/siffi/](https://cheatography.com/siffi/)

Not published yet.  
 Last updated 7th May, 2021.  
 Page 1 of 3.

Sponsored by **ApolloPad.com**  
 Everyone has a novel in them. Finish Yours!  
<https://apollopad.com>

### Presentation

- Paraesthesia in palmar 3 1/2 fingers (median nerve)
- Night symptoms (increased hand volume) - patient complains of having to "wake up and shake it off"
- Pain over carpal tunnel
- Patients often think their whole hand is numb (poor localisation)
- Pain can refer to the elbow
- Palm symptoms indicate higher up involvement (pronator teres, TOS) as palmar cutaneous branch travels outside of the carpal tunnel
- Symptoms aggravated by gripping activities
- Hand weakness/atrophy may occur of the hand (thenar - ape hand)
- Patient complains of dropping things (decreased sensation)
- May have autonomic symptoms (tight swollen feeling, skin colour changes, hand temperature changes)
- Hypertonicity of Cx, scalene, pecs, pronator and wrist flexors
- ROM may not be affected but can reproduce complaint in flexion/extension - consider lunate
- Limited active thumb abduction
- Look for cutaneous findings (ulcerations, blistering, sclerodactyly, nail dystrophy)
- +ve Tinel's, Phalen's , Manual Carpal compression (most sensitive)
- Numbness of 5th digit/dorsum , consider neuropathy of alternate origin
- Weakness in LOAF muscles (1st and 2nd lumbricals, Opponens pollicis, Abductor pollicis brevis, Flexor pollicis brevis) - Pinch grip
- Consider double crush - Cervical arthropath, Cx disc, TOS, Pronator syndrome
- Consider other structures - ligament of Struthers, lacertus fibrosis

**Bilateral hand involvement - central cord lesion until proven otherwise (MRI)**

### CPR

#### Least 4 of the 5 findings:

- Shaking hands to relieve symptoms
- Wrist rate >.67 (thickness to the width)
- Symptom severity scale >1.9
- Diminished sensation in thumb
- Age >45 years old



### Imaging

- Imaging only needed if bony compression is suspected
- MRI can be used to determine Cx radiculopathy/soft tissue pathology
- US (more sensitive than MRI)
- EMG

### DDx

- Cx radiculopathy
- TOS
- Compartment syndrome
- Diabetic neuropathy
- Lateral/medial epicondylitis
- MS
- Regional pain syndrome
- SOL - Flexor tenosynovitis/ganglions

### Management

- Myofascial release of forearm, wrist and hand - pronator, wrist flexors and carpal tunnel
- Median nerve flossing
- SMT of Cx or carpal restrictions
- Kinesiotape
- Splinting (night pain)
- Home exercises - Cx spine, scalene, pecs, pronator and wrist flexors, chin retraction, carpal tunnel mobilisation, median nerve glide and floss
- Advise rest - avoidance of repetitive wrist flexion/extension
- Vitamin B6
- Weight loss if obese
- Patients with significant motor deficits/not improving with conservative care consider referral for injections/surgery

Factors of success of conservative care:

1. Age >50 years
  2. Duration >10 years
  3. Constant paraesthesia
  4. Stenosing flexor tenosynovitis
  5. +ve Phalens test in >30 seconds
- >2 factors - conservative management successful in 83% of cases  
if 3 - 7% success  
if 4 or 5 - 0% success

