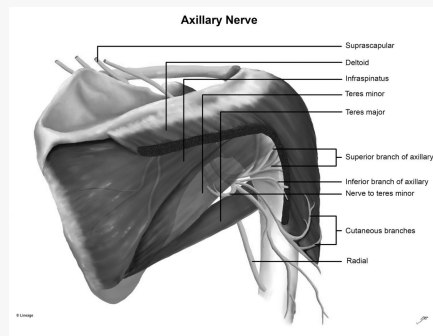


### Axillary Nerve



- Posterior cord of the brachial plexus, anterior to the subscapularis muscle
- Travels inferior to the glenohumeral joint capsule
- Passes through quadrangular space
- Axillary nerve splits into anterior and posterior division
- Anterior division = motor innervation to anterior and middle heads of deltoid
- Posterior division = motor innervation to posterior deltoid and teres minor
- Terminates as the superior lateral cutaneous nerve (innervates lateral shoulder)
- C5-C6

### Causes

- Skiers, footballers, rugby, baseball, hockey, soccer, weight lifting, wrestling
- Chronic compression occurs in young adults who are overhead throwers
- Carrying a heavy backpack/ misuse of crutches
- Overdeveloped or hypertrophic muscles forming quadrangular space
- Ganglion/paralabral cyst
- More common in the dominant shoulder
- Brachial Neuritis (Parsonage-Turner Syndrome)
- Rare in isolation
- Older people with GH dislocation more predisposed

C

By **Siffi** (Siffi)  
[cheatography.com/siffi/](https://cheatography.com/siffi/)

Published 9th November, 2021.  
Last updated 9th November, 2021.  
Page 1 of 3.

Sponsored by **Readable.com**  
Measure your website readability!  
<https://readable.com>

### Presentation

- Dull, poorly localises shoulder ache
- Can be after sporting event or blunt force to the shoulder (shoulder dislocation can be related to AN)
- Vague deltoid numbness or paraesthesia
- Sensory symptoms often worse at night
- Deltoid weakness may be present ( rapid fatigue with overhead throwing)
- Exacerbated by arm abduction and external rotation
- Point tenderness of quadrangular space
- Weakness in abduction, external rotation
- Deltoid atrophy if chronic
- Assess for changes in limb (cyanosis, pallor, splinter haemorrhages) for lesions pressing on posterior circumflex artery as it exits the quadrangular space (Quadrangular space syndrome (QSS))
- Assess ipsilateral neck and upper extremity
- Assess other nerves (Spinal accessory, suprascapular, long thoracic, musculocutaneous, radial)

### DDx

- Cx radiculopathy
- TOS
- Rotator cuff tear
- Brachial plexopathy
- QSS
- Brachial neuritis
- GH f#/dislocation
- Subacromial impingement syndrome
- Herpes Zoster



### Imaging



- X-ray rule out bony pathology/ if trauma
- MRI to rule out lesions and look for atrophy of teres minor/deltoid
- EMG gold standard
- MRI if compressive/inflammatory causes

### Management

Selective rest and modifications

ROM exercises

Cross friction massage / myofascial release to muscles of quadrangular space

- GH mobilisation

- Cross body and posterior capsule stretching

- Rotator cuff strengthening

- Avoidance of positions that place axillary nerve in traction

- NSAIDs

- If failure to restore function in 3-6 months , consider surgical referral

- Traumatic cases can be managed non-surgically (reduction, immobilised for 4-6 weeks in the young and 7-10 days in the elderly then a rehab program - muscle strength and shoulder mobility) but there is a risk of permanent paralysis

-Neuropraxic patients expect recovery within 6-12 months

- Axonotmesis recovery is high, but can take many months, if no signs of recovery within 6-9 months, consider surgery

- Neurotmesis patients should have surgery

### Prognosis

- Low grade + GH dislocation recovery within 7 months

**Complications:** Permanent numbness to the lateral shoulder region, atrophy of the deltoid and teres minor muscles and chronic neuropathic pain

