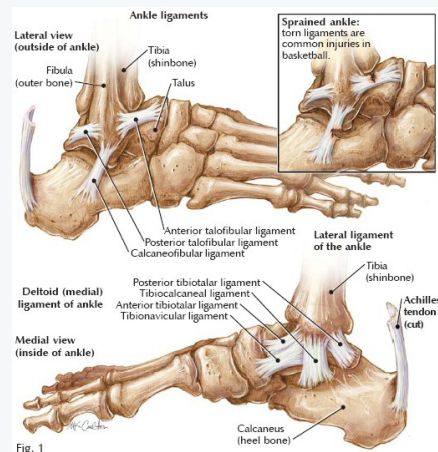


Ankle anatomy



Deltoid ligament limits eversion, dorsiflexion and plantarflexion - rarely injured (strongest ligament), isolated sprains are **rare**
 Most commonly sprained = Anterior talofibular ligament (**ATFL**) - due to it being the weakest ligament
 and Calcaneofibular ligament (**CFL**)

Complications

- Chronic pain/disability
- Recurrent Ankle instability
- Osteochondral defects of the talus
- Peroneal tendon injuries
- Neurovascular injuries
- Tibiotalar OA
- Pantalar OA

Classification

- Grade I: Stretch with no macroscopic fibre disruption
- Grade II: Partial Fibre disruption
- Grade III: Rupture (Usually associated with another injury, usually f##) + syndesmotic structures + tendon rupture

Demographics/Causes

- Physically active people (basketball, football, soccer, soldiers)- most common
 - Males and females affected equally
 - Highest in 15-19 yo
 - Limited ankle dorsiflexion
 - Previous Hx of ankle sprain
 - Lateral ankle = inversion sprain
 - Medial ankle = eversion sprain (rare due to limited eversion of the ankle)
- Usually occurs due to eversion/pronation and abduction/external rotation
 Foot planted in pronation, upper body falls laterally -unexpected misstep/landing on uneven surface

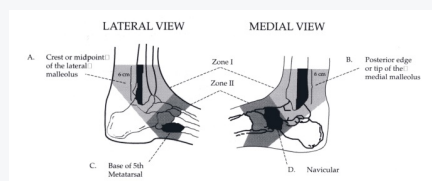
Presentation

- Sudden onset of pain from "rolling the ankle"/landing from a jump/stepping into a hole
- Pts may recall a pop at the time
- Pain from mild aching to intense (worse at the end of the day)
- Aggravated by weight bearing
- Swelling (worse at the end of the day)
- Rapid bruising and swelling could indicate rupture
- Bruising and discolouration gradually gravitates towards foot
- Cold foot and or paraesthesia = neurovascular compromise/compartment syndrome
- Tenderness over affected ligament
- ROM may be painful on passive inversion/dorsiflexion (lateral) or passive eversion (medial)
- +ve Talar tilt, +ve Anterior draw test, +ve ankle eversion stress test +ve external rot test
- Syndesmotic sprains can be differentiated with the fibular squeeze test (rare in the general population, ankle in high forced ext rot and/ankle dorsiflexion)
- Palpation dorsalis pedis and posterior tibia pulses + sensation over foot for neurovascular compromise
- Suspect instability = recurrent sprains, difficulty running on uneven surfaces, cutting and jumping, giving way
- Palpation of ATFL, CFL and PTFL and medial ankle and entire fibula to assess for f# (pain and crepitus)
- Assess foot : especially navicular, midfoot and 5th metatarsal
- FADI, FAAM, LEFS and sports ankle rating system

Red Flags

- Significant Instability
- Significant Crepitus
- Catching
- No response to conservative care after 4-6 weeks
- MRI/US considered

Imaging



- **Ottawa Ankle rules:**
- **Ankle X-ray** = bone tenderness at A
- Bone Tenderness at B
- Inability to weight bear both immediately and on physical exam
- AP, Lat, Mortise views
- **Foot X-ray** = Bony tenderness at C and D
- Inability to weight bear both immediately and on physical exam
- AP, lateral, oblique
- Moderate spec, high sens
- Should **not** be used:
- A distracting injury

- Intoxication
- Diminished lower extremity sensation
- Head injury/cooperation disorders

DDx

- Syndesmotic sprain
- F# (Lisfranc)
- Dislocation
- Intraarticular meniscoid
- Subtalar sprain
- Achilles tendinopathy
- CRPS



By **Siffi** (Siffi)
cheatography.com/siffi/

Published 3rd November, 2021.
Last updated 3rd November, 2021.
Page 2 of 4.

Sponsored by **ApolloPad.com**
Everyone has a novel in them. Finish
Yours!
<https://apollopad.com>

DDx (cont)

- Inflammatory Arthropathy

Management

- Usually heal quickly, but some report pain, instability, crepitus, weakness, stiffness, swelling
- PRICE for 72 hours after injury
- Ice/ice massage for 15 minutes each hour
- NSAID advice
- All sprains may require complete immobilisation
- Prevention = taping/using devices (air splint/velcro brace)
- Then manual therapy
- Joint mobilisation
- Transverse friction massage of affected ligament
- Myofascial release and stretching of gastrosoleus
- Ankle Alphabet
- When ROM, pain and swelling improves, move onto strengthening
- Strengthening includes isometric contractions against immobile object then to dynamic resistance with weights, tubing, bands
- Strengthening of dorsiflexion, plantar flexion, inversion and eversion
- Strengthening of Peroneals (resisted eversion)
- If ankle is instable = hip abductor strengthening
- Wobbleboard to gain proprioception
- Return to activity starts with straight line then progress to forwards/backwards, side to side, pivoting cutting motions
- Return to play = full pain free ROM and ankle strength >80-90%
- Grade III/ syndesmosis involvement = surgical consult (younger patients with occupation/activities that places them at higher risk of re-injury)
- If ligamentous laxity - immobilise and crutches should be given, refer to orthopaedic surgeon (could be osteochondral defects of the talus, peroneal tendon, intra-articular loose bodies and fractures)

Whitman's CPR

- Symptom's worse when standing
- Symptoms worse in the evening
- Navicular drop >5mm
- Distal tibiofibular joint hypomobility
- Predicts the success of manipulation and exercise
- 3 out of the 4 variables above = >95% success rate

Prognosis

- Mild- Moderate sprains usually recover within 7-15 days
- Instability and defects occur in 25-40% of patients

