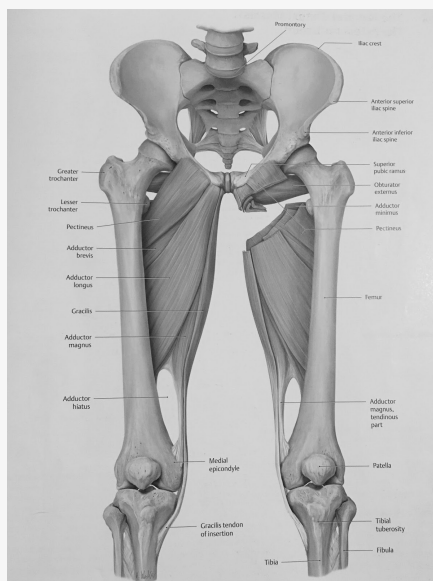


Adductor Muscles



More information about this on the upper leg muscles cheat sheet

Sudden change of direction - rapid adduction of the hip against abduction force - stresses tendon

Sudden acceleration (sprinting) - most common

Most injured at the musculotendinous junction - area of poor blood supply and rich nerve supply

Adductor muscles

Contain: adductor Longus, adductor brevis, adductor Magnus, gracilis, pectineus, obturator externus

Innervated by obturator nerve apart from the pectineus (femoral)

Magnus/longus is the most strained due to mechanical disadvantage - not made for explosive movements & longus has low tendon to muscle ratio

Types

Acute: involves musculotendinous junction/muscle belly

Chronic: proximal irritation at the tendinous junction

Grade 1: Pain with minimal loss of mobility or strength

Grade 2: Partial loss of strength and function

Grade 3: complete muscle/tendon disruption with loss of function

Demographic

People who play sport which involves forceful eccentric contraction of the adductors (especially in external rotation and abduction of the leg)

- Kicking, sprinting, forceful trunk rotation, side to side cutting, sudden changes in direction

- Ice hockey, soccer, football, rugby running, tennis, basketball, powerlifters (sumo stance)

- Usually occurs again after previous adductor injury

- inadequate physical conditioning (decreased ROM, previous hip/groin injury, inadequate stretching/strengthening of adductors)

- Athletes with thigh adductor : abductor strength ratio of <4:5



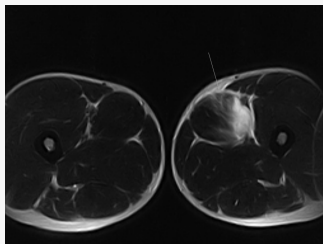
Demographic (cont)

- Age
- Excessive pronation or leg-length discrepancy

Presentation

- Sudden onset of pain on proximal inner thigh , can radiate distally
- Pain provoked by movement , muscle stretch and eccentric contraction
- Bruising/swelling in moderate-severe injuries
- Tenderness over inguinal ring and proximal inner thigh
- Pain on passive abduction or resisted adduction
- +ve thigh adductor squeeze test (adductor Magnus and gracilis)
- Neurological testing unremarkable, but sometimes adductor weakness and or sensory loss over medial thigh can occur (obturator neuropathy)
- Assessment of lumbar spine, SI and hip (biomechanical)
- Assess for hyperpronation, lower crossed , glut med weakness

Imaging



- MRI showing oedema of adductors on the right
- Plain film radiographs can help rule out tendon avulsion or bony pathology (AP and frog-leg of the hip)
- Ultrasound can be considered if no bony pathology is suspected

Ddx

- Osteitis pubis (tenderness over pubis symphysis)
- Athletic pubalgia (sports hernia, abdominal pressurisation tests +ve)
- inguinal hernia
- hip pathology (FAI, avascular necrosis, SCFE, LCP, transient synovitis , degeneration, ff#)
- GI/GU pathology
- Referred lumbrosacral pain
- Neuropathy of obturator, iliohypogastric, ilioinguinal nerve
- Iliopsoas bursitis/tendinitis
- Rec fem tendinitis

Management

- RICE for 48 hours
- TENS , US, STW
- Rehab phase 1: hip ROM and stretching of uninvolved muscles, isometric adduction, non weight bearing progressive resistance for hip flexion, extension and abduction, strengthening of trunk, upper body and contralateral lower extremity
- Balance board exercises
- Patient can carry onto phase 2 when patient can perform pain free concentric adduction
- Phase 2: ball squeezes, sumo squats, single leg stance, standing adduction with resistance band and seated, lunges, lateral squats and lat lunges, sliding board, patient advised to swim or cycle
- When patients can passively move and the affected side and strength equal to than the unaffected, phase 3 can begin
- Phase 3: more load, intensity and speed, sport specific drills
- Athletes are allowed to return to sports when they regain full pain free ROM and 75% full strength
- Should be better within 4 weeks if acute. If moderate-acute , 4-8 weeks recovery, chronic up to 6 months
- Reassure patient that discomfort when returning is not uncommon
- Consider LP SMT, STW, myofascial release
- Address biomechanical dysfunction
- Patient advised to wear proper footwear and not run on hard/soft surfaces
- Adductor strengthening can prevent strains
- Consider surgical referral if strain is no better with conservative care, full thickness tears/avulsion injuries with persistent weakness of the affected limb

Prognosis

- Favourable
- Minimal pain and normal function if fully rested and rehabed
- >20 weeks after injury recovery for athletes

