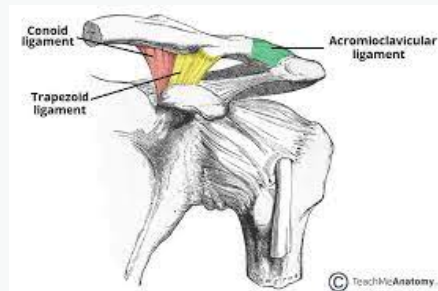


Ligaments



Superior, inferior, anterior, posterior AC ligaments = Prevents A/P shear and provides horizontal stabilisation - superior most important for stability

Coracoclavicular ligaments = Conoid and Trapezoid - Resists superior and inferior translation

Rockwood Classification

Type I – mild, unseparated sprain of the AC ligaments with no disruption of the coracoclavicular ligaments.

Type II – complete disruption of the AC ligaments with joint separation (less than 4 mm or 40% difference) and sprained but intact coracoclavicular ligaments.

Type III – complete disruption of AC and coracoclavicular ligaments with joint separation and inferior displacement of the shoulder complex.

Type IV – complete disruption of AC and coracoclavicular ligaments with posterior displacement of the clavicle through the fibers of the trapezius, and detachment of deltoid and trapezius muscles from the distal clavicle.

Type V – complete disruption of the AC and coracoclavicular ligaments with significant inferior displacement of the shoulder complex from the clavicle as compared to a typical Type III injury.

Type VI – complete disruption of the AC and coracoclavicular ligaments, and the clavicle has dislocated inferiorly, below the coracoid process.

Mechanism of injury

- Fall onto the shoulder with arm in an adducted position
- FOOSH/Elbow
- Makes up 40-50% of athletic shoulder injuries at 2-4th decade of life
- Rugby, Ice hockey, football, wrestling players are more susceptible



By **Siffi** (Siffi)
cheatography.com/siffi/

Published 2nd November, 2021.
Last updated 2nd November, 2021.
Page 1 of 3.

Sponsored by **Readable.com**
Measure your website readability!
<https://readable.com>

Presentation

- Pain and swelling on anterosuperior aspect of the shoulder after trauma
- Symptoms start in the traps, shoulder and neck but move to the AC joint
- Painful with bench pressing, dips or laying on the affected side
- Bruising/defomity on clavicular prominence

Diagnostic findings

- Swelling, bruising and deformity on clavicular prominence
- Tenderness over AC
- Feeling of giving way on palpation of distal clavicle (+ve Piano Key sign)
- ROM painful and limited - abduction most affected
- +ve Cross body adduction
- +ve BvR
- +ve Paxino
- +ve Buchberger test
- Associated with fractured clavicle, impingement syndromes and neurovascular insults
- Consider active vs passive ROM - Rotator cuff
- Buchberger test distinguishes subacromial impingement from AC joint sprain (more pain in external rotation)
- Evaluate entire clavicle and SC for other injuries
- Perform full neurovascular exam on affected side

DDx

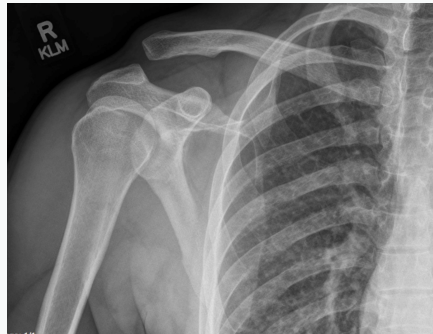
- Clavicular f#
- Rotator Cuff lesion
- Shoulder Anterior impingement syndrome
- Shoulder dislocation
- Labral injury
- Osteolysis of distal clavicle
- Neoplasm
- Rheumatologic disease
- Cervical spine/viscerosomatic referral
- Shoulder osteoarthritis
- Adhesive Capsulitis
- Erb Duchenne
- Septic Arthritis



DDx (cont)

- CRPS

Radiographs



AP, lateral, and axillary lateral views

- Not often apparent on x-ray - Zanca view (tilting of beam 10-15 degrees caudal and bilateral AP views), weighted stress views
- MRI only used to rule out other pathologies of the shoulder
- X-ray shows AC joint separation (type 3) due to ligament injury

Management

Grade I + II - Protection, immobilisation (sling for 3-10 days), mobility and strengthening

- Passive mobility exercises (avoid exercises that involve behind back internal rotation, crossbody adduction and forward elevation)
- Strengthening (closed chain scapula stability exercises - scapula clocks)
- Prognosis is favourable
- Usually regains motion by six weeks and regain normal function within 12 weeks
- Surgery for IV-VI types (six week immobilisation with up to six months recovery time)
- AC joint arthritis and joint pain can occur in future
- Type III-VI should have regular appointments by a orthopaedic surgeon/physician

C

By **Siffi (Siffi)**
cheatography.com/siffi/

Published 2nd November, 2021.
Last updated 2nd November, 2021.
Page 3 of 3.

Sponsored by **Readable.com**
Measure your website readability!
<https://readable.com>