

What is Electrocardiogram?

An electrocardiogram (ECG or EKG) is a non-invasive test that measures the electrical activity of the heart. It can help diagnose heart conditions, such as arrhythmias, heart attacks, and coronary heart disease.

Patient details.

Make sure there is patient's details such as name and also ID to make sure it's a 'right patient'
Date and time when is the ECG recorded.

ECG calibrations.

The standard ECG calibrations are:

- 1) 10 millimeters (mm) per millivolt (mV)
- 2) A calibration signal of 1mV should produce a rectangle that is 10 mm high and 5 mm wide.
- 3) The calibration speed of a standard ECG is usually 25 mm per second (mm/s).
- 4) The calibration may be changed if the waveforms are too small or large.

Rate

Calculate the patient's heart rate (HR) by using these 3 methods:

1. R-R interval in 6 second method (R-R total in 30 big boxes)
2. R-R interval of big boxes (300/total of big boxes in R-R)
2. R-R interval of small boxes (1500/total of big boxes in R-R)

Normal HR would be 60bpm - 100bpm.
Tachycardia > 100bpm
Bradycardia < 60bpm.

P wave

A "P wave" in an ECG (electrocardiogram) represents the electrical depolarization of the atria, meaning the wave seen on the ECG when the upper chambers of the heart (atria) are contracting, and is typically the first small positive deflection seen on the tracing, indicating the start of a cardiac cycle.
The P wave interpretation:
Present > sinus
Absent > junctional
Fibrillate > Atrial fibrillation
Saw tooth > Atrial flutter

QRS complex

The QRS complex is the main spike seen in the standard ECG. It is the most obvious part of the ECG, which is clearly visible. The QRS complex represents the depolarization of ventricles. It shows the beginning of systole and ventricular contraction.
Normal - less than 3 small boxes (<0.12sec), Narrow
Abnormal - more than 3 small boxes (>0.12sec), Broad.
Frequent ventricular ectopic beats (VEBs) in a pattern could be a:
Bigemini - Sinus, PVC

QRS complex (cont)

Trigemini - Sinus, sinus, PVC,
Quademini - Sinus, sinus, sinus, PVC
Consecutive premature ventricular contractions happen back-to-back without a normal beat in between such as:
Couplet: Two consecutive PVCs
Triplet: Three consecutive PVCs
Salvo: A rapid sequence of four or more PVCs

Rhythm

We determine rhythm in an ECG (electrocardiogram) because it provides crucial information about the regularity of the heart's electrical activity.
Regular - sinus, av block,
Irregular - sinus arrhythmia
Irregularly Irregular - fibrillation
Regularly irregular - PVC

P-R interval

The P-R interval is the time between the beginning of the P wave and the beginning of the QRS complex on an electrocardiogram (ECG). It's a measure of how long it takes for an electrical impulse to travel from the atria to the ventricles of the heart.

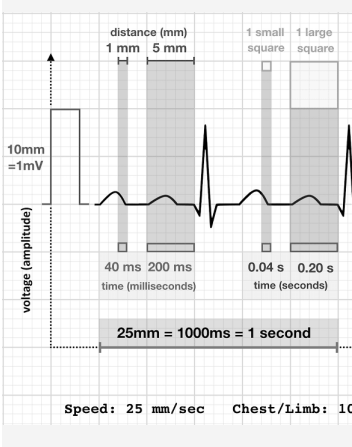
P-R interval (cont)

A normal P-R interval is usually between 0.12sec - 0.20sec (3 small boxes - 5 small boxes). Prolonged P-R interval could be due to AV block.
Undetermined usually for AF, AFlutter, VT, VF (absent P wave)

Interpretation

With all the data you obtained from the ECG rhythm, you should be able to come up with the rhythm interpretation like this:
Sinus Rhythm
Atrial Fibrillation
Ventricular Tachycardia

ECG standard calibration



By **Shasha Adam**
(shashaadam)

Not published yet.
Last updated 8th February, 2025.
Page 2 of 2.

Sponsored by **Readable.com**
Measure your website readability!
<https://readable.com>

