

Anatomy

Testicular cancer presentation will often be via a painless swelling, or mass in the scrotum. Sometimes there is localised discomfort or pain, with an associated heaviness.

If there is pain in the abdomen this can be suggestive of pelvic or abdominal metastases, and should be investigated accordingly. Elevated serum markers should be assessed. These can help the physician distinguish between different types of testicular cancers.

The testicles (testes) are two small, oval-shaped organs located behind the penis in a skin sack called the scrotum.

Each testis lies within a fibrous capsule known as the **tunica albuginea**, within the scrotum.

The testicles are located outside the body because sperm develop best at a temperature several degrees cooler than normal internal body temperature.

The germ cells inside the seminiferous tubules (sertoli cells) create sperm. The sperm move into the epididymis where they mature. They are stored there for a few weeks until they eventually move up the vas deferens to combine with fluids from the prostate and seminal vesicles to form what you normally think of as semen. The whole process takes about 7 weeks.

The leydig cells distributed throughout the testicle are the body's main source of testosterone. Testosterone, the male sex hormone, is essential to the development of the reproductive organs and other male characteristics such as body and facial hair, low voice, and wide shoulders. Without enough testosterone, a man will probably lose his sex drive and suffer from fatigue, depression, hot flashes and osteoporosis.

Lymphatics play an important part in the management of testicular cancer patients.

Anatomy (cont)

The lymphatics directly from the testes follow the spermatic cord, through the inguinal ring, along the iliac nodes and to the para-aortic nodal chain. These lymphatic chains ultimately determine the radiation fields.

Epidemiology and Aetiology

Testicular tumours are **relatively rare**, representing approximately 1% of all cancers.

In men aged between **20 and 34** it is the most common cancer and most common cancer killer

It is associated with **cryptorchidism**, which is maldescent of the testes from the abdomen. There is an increased risk 10 to 40 times higher.

Pathology

The breakdown of the tumour types expected for testicular tumours are **95 % Germinal**, and the remainder non-germinal.

The germinal tumours are formed from the germ cells, which form sperm within the testicles.

70 % of germinal tumours are seminoma, and the rest are teratomas.

Over the age of 50 tumours tend to be of non-germ cell origin.

Seminoma are sensitive to radiation and often present early at stage 1 where an Orchidectomy is performed and then prophylactic para-aortic node irradiation is delivered.

Teratoma would be treated with cytotoxic chemotherapy as this is a chemosensitive structure and because there is greater chance of distant spread at presentation.

Spread

Seminoma is very **predictable** in its spread, and at presentation regional lymph nodes will be present in 25 % of cases for seminoma, 40 % for teratomas, and 50 % for embryonal carcinomas.

Spread is most commonly in the para-aortic lymph node group. Local spread may be present to the epididymis and spermatic cord.

Diagnostic work-up

General - history and physical examination

Bloods - FBE, serum assays

Medical Imaging - **Testicular ultrasound** is the first procedure for scrotal abnormality, followed by chest imaging and CT of the abdomen/pelvis to assess nodal involvement.

Surgery consists of an inguinal orchidectomy, where the affected testicle is removed through the groin. This is both a **diagnostic and therapeutic procedure**.

The complete removal means an accurate diagnosis can be made through histopathology and the primary disease has been removed from the patient.

If the surgeon removed all or part of the testes through an incision in the scrotum, then there would be a **high risk of seeding** within the scar. This technique would also disrupt normal lymphatic flow, altering the natural history of the disease. If partial removal were done, there would be a **high risk of local recurrence** or continued growth of the primary disease.

Staging

There are a number of staging systems used for testicular cancers.

*the **Royal Marsden system** is the most widely used one.

The Marsden system, it is broken up into 4 stages.

The Royal Marsden staging system

STAGE	
I	Limited to testis
IIA	Nodes <2 cm
IIB	Nodes 2–5 cm
IIC	Nodes 5–10 cm
IID	Nodes >10 cm
III	Nodes above and below diaphragm
IV	Extralymphatic mets

Management

For non-seminomas and patients with advanced disease, a radical orchidectomy and chemotherapy will be administered.

Chemotherapy regimes have improved considerably for non-seminoma tumours in the last couple of decades. Therefore after surgery, Platinum-based multi-agent chemotherapy will be delivered to the patient.

Radiotherapy will not play a role in the management unless there is a large residual mass postchemotherapy.

For **pure seminoma**, surgery via orchidectomy will be undertaken. This is followed by **radical radiotherapy**. Seminoma is highly sensitive to radiation; therefore high doses are not required to be tumourcidal. This presents as an interesting scenario for the radiation oncologist, as these men are young and easily curable (greater than 90 % cure rate). Yet there are a number of critical structures that we will need to discuss.

Simulation

The radiation fields that are used to treat testicular cancer will be dependent upon the disease stage, the administration of chemotherapy and the radiation oncologist's preference.

There are usually three options:

For **early stage disease** only the para-aortic nodal group is irradiated.

Simulation (cont)

For **further advanced disease**, a dog-leg technique will be used to include the iliac nodal group on the ipsilateral (affected) side.

With **bulky disease in the para-aortic** it is possible that the contralateral pelvis will be irradiated - an "inverted Y" technique. There will be a central pelvic shield to minimise toxicity to the bladder and bowel.

The treatment technique for both the '**dog-leg**' and **abdomen techniques** is using AP/PA photons.

The energy can be dependent on the patients' AP separation, ranging from 6 to 18 MV.

The patient will be positioned supine on carbon fibre, with a neck support, bolster under knees and ankle support to ensure reproducible leg position.

The radiation fields are designed based on the patient's lymphatic chains. Everyone's lymphatics are slightly different, so we need to know where they are.

The classic **dog leg technique** has UL field size is set at T10. The field width is approximately 9 to 12 cm in the para-aortic region, and 2 cm coverage either side of the ipsilateral pelvic nodes. This is achieved by angling at the level of the fourth and fifth lumbar vertebrae towards the affected side.

The Lower level is at the top of the **obturator foramen**, but there is no need to include the surgical scar within the field unless the is a testis capsule was compromised and there **risk of seeding**. The radiation oncologist may like to see a **radio-opaque marker** along the **scar** so that it is **visualised on CT**. Most often that not, the LL will run about half way through the scar

Para-aortic strip

Not published yet.

Last updated 24th October, 2016.

Page 2 of 4.

Simulation (cont)

If the radiation oncologist has prescribed radiation to the **abdomen only**, similar information to the dog-leg technique will need to be acquired.

The field width is normally 8 – 10 cm wide that may not require any shielding. The upper level of the field will again be the junction of T10 and T11, with the lower level the junction of L5 and S1. There will be little to no shielding required for this technique, so an **isocentric technique** is suitable.

The information to be acquired at simulation/planning for both the dog-leg and para-aortic techniques are essentially the same, as follows:

-Tattoo positions (centre dependant) eg isocentre, ½ AP laterally, TOX/ML, UBP/ML

-Stretch TOX (Tip of xiphi-sternum) to UBP (upper border of pubis)

-UBP – BOP (Base of penis)

-A planning CT throughout the treatment volume will be acquired. This will be used to delineate the kidney volume and the field definition for the patient.

Supra-diaphragmatic disease

It is unlikely that we will treat above the diaphragm for testicular cancer. If we were to treat a residual mass, the field dimensions are:

-Lateral edges to cover the rib cage

-superiorly is 2 cm above palpable disease

-inferiorly is the 10th rib

-similar doses as the abdomen 25/20/5, with boosts to any bulky disease in the neck or mediastinum up to a dose of 30 - 40 Gy.



By Molly

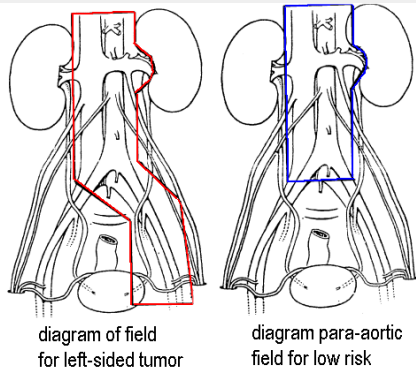
cheatography.com/molly/

Sponsored by **ApolloPad.com**

Everyone has a novel in them. Finish Yours!

<https://apollopad.com>

Typical field borders for dog-leg technique



Planning

The planning for these patients is not usually complex, as **the technique is just opposed photon fields.**

From the CT, the kidneys will be marked.

Figure A (lower image) is a DRR of a patient that was planned for a dog-leg technique for Seminoma. Notice the long field length, the heavy shielding (represented by the horizontal lines), and the partial irradiation of the kidneys can be seen in the upper planning images. There is a higher risk of disease on the ipsilateral side within the para-aortic region, so there is greater coverage on that side. Notice how there is slightly more kidney within the field on the right side compared to the left.

A senior member of the planning staff will check the data:

The isocentre is in the correct position;
 The dose is even across the treatment volume;
 Dose to critical structures - Left and right kidneys;
 Correct field size, monitor units, patient position, TD used in the calculations
 Once the plan has been checked, and everything is satisfactory, the patient is ready to commence treatment.

Planning data

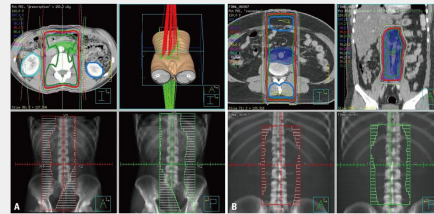


Figure 5.5 Planning data including cross sectional transverse slice with isodoses (upper images), a skin rendered image with radiation beams superimposed, and Digitally reconstructed radiograph (DRR) images showing anterior and posterior views of fields with shielding in place.

Treatment

Since the tumour type is particularly sensitive to radiation, large doses do not need to be prescribed.

Dose between 24 and 30 Gy in 1.5 -1.6 Gy per fraction.

If there is a persistent mass, then a boost will be delivered to an extra 5 - 10 Gy.

It is just as well that we can deliver **low daily doses since it is such a large area to be treated**, with the **potential for significant treatment toxicity**. As with most radiation therapy techniques there are some critical structures present:

- The **contralateral testes** - probably the most sensitive.
- Kidneys** - will be shielded as much as possible while covering the nodal groups.
- Bowel** - can't do much about this - medication as required.

If the tumour is sensitive to radiation, it follows that **the testis is sensitive to radiation also.**

1 - 2 Gy before sterility is induced

Most patients are informed that it may take a while before they can conceive. Apart from shielding to the lowest dose possible, for young men who wish to have children, **sperm banking is advised.**

Usually a **FBE (Full blood examination)** will be performed at simulation to establish a baseline on blood counts. Bloods will then be taken weekly through out the treatment from there.

Treatment (cont)

When para-aortic nodes are being treated alone, then there is little bone marrow within the radiation fields, but **a dog-leg will irradiate a fair amount of the pelvis**, which will affect the bone marrow and **may alter the blood work up.**

Acute side effects: Significant erythema is not expected, due to the low doses, **nausea and diarrhoea** are extremely likely due to the sheer size of the fields, some **tiredness** may be experienced after about two weeks of treatment.

VERIFICATION

Weekly imaging will be a minimum for these patients; many clinical centres may acquire images each fraction

Due to the close proximity of the fields to the kidneys, and their relative sensitivity to radiation, **any lateral movement of the fields will be watched closely.**

Complications

Late toxicities:

Dyspepsia (a common condition and usually describes a group of symptoms rather than one predominant symptom.) i.e Belly pain or discomfort. Bloating. Nausea. Loss of appetite. Heartburn. Burping. Regurgitation.

Peptic ulcers

Intestinal obstruction

Gastritis (a group of conditions with one thing in common: inflammation of the lining of the stomach.)

Impaired hormonal function

Spermatogenesis impairment.

Follow up

The radiation oncologist will follow up the patient around six weeks post completion of the radiation therapy.

After six weeks any radiation-induced side effects should have subsided, and there should be some indication of tumour response.

C

By **Molly**
cheatography.com/molly/

Not published yet.
Last updated 24th October, 2016.
Page 4 of 4.

Sponsored by **ApolloPad.com**
Everyone has a novel in them. Finish Yours!
<https://apollopad.com>