

NS Function and Divisions

What are the functions of the NS?

Sensation, integration, response

What are the divisions and subdivisions of the NS?

CNS and **PNS** (in PNS: somatic sensory, visceral sensory, somatic motor, and the autonomic nervous system which has the parasympathetic and sympathetic nervous systems)

Nervous Tissue

What are the characteristics of neurons?

1. Highly specialized to conduct nerve impulses 2. Long lived 3. Don't divide 4. High metabolic rate (takes a lot of energy)

What are the structures of neurons?

Neurosoma (cell body), dendrites (receivers), axons (senders)

Describe sensory neurons

bring info to the CNS

Describe interneurons

integrate information IN THE CNS

Describe motor neurons

responses leaving the CNS

What is the most common neuronal variety throughout the body?

Multipolar neurons

Neuroglia

What are the 6 types of neuroglia?

CNS: Astrocytes, microglial, ependymal cells, and oligodendrocytes **PNS:** Satellite cells and schwann cells

Neuroglia (cont)

What is the function of astrocytes?

Support, control ionic environment, nourishment, communication, it has many varied in functionality

What is the function of microglial cells?

Phagocytosis- remove debris, immune function

What is the function of ependymal cells?

Involved in the production and circulation of cerebrospinal fluid

What is the function of oligodendrocytes?

Form the myelination in the CNS for insulation

What is the function of satellite cells?

Support and environmental regulation (surround neurosomas)

What is the function of schwann cells?

For myelination in the PNS for insulation

What is myelin?

A plasma membrane of water, lipids, and proteins that insulates axons

What is the function/benefit of myelin?

Increases the speed of conduction (gaps are necessary)

What influences conduction speed?

The diameter of the nerve fiber and myelin

General NS Organization

What is the difference between gray and white matter?

Gray matter lacks myelin

Where is gray/white matter in the spinal cord?

Gray: inner portion White: outer portion

General NS Organization (cont)

Where is gray/white matter located in the brain?

Gray: Cortex (cerebrum and cerebellum), superficial **White:** tracts, deep to cortex **Brain Nuclei:** deep clusters of gray matter embedded in white matter

Spinal Cord Structure

What are the functions of the spinal cord?

1. Conduction- carry impulses up and down **2. Neural Integration-** decision making **3. Locomotion-** simple patterns like walking **4. Reflexes-** quick reaction without brain

What are the major structures of the spinal cord?

Cervical enlargement, lumbar enlargement, conus medullaris (end of the spinal cord), cauda equina (horse tail), and terminal filum (anchors conus medullaris)

What are the regions of the spinal cord?

Cervical, thoracic, lumbar, sacral

Describe the posterior (dorsal) horn

Sensory processing (sensory neurons)

Describe the anterior (ventral) horn

Send motor signals (motor neurons)

Describe the gray commissure

connects the right and left side of the spinal cord and allows for side to side information transfer

Describe the lateral horn

ONLY in thoracic and lumbar region of SC, for autonomic nervous system (specifically the sympathetic division)



By **katwalker11**

cheatography.com/katwalker11/

Published 1st April, 2021.

Last updated 30th March, 2021.

Page 1 of 4.

Sponsored by **ApolloPad.com**

Everyone has a novel in them. Finish Yours!

<https://apollopad.com>

Spinal Cord Structure (cont)

Describe the dorsal (posterior) funiculus
| ascending tracts (sensory info up to the brain)

Describe the ventral (anterior) funiculus
| descending tracts (motor commands down from the brain) and a little ascending

Describe the lateral funiculus
| ascending and descending tracts

What is the function of commissural fibers in white matter of the spinal cord?
| carry information from side to side

Protection of the Spinal Cord

What protects the spinal cord?
| 1. Vertebral column 2. Meninges 3. Cerebrospinal fluid (CSF)

What are meninges?
| protective membranes

What are the functions of the meninges?
| 1. Cover and protect the CNS 2. Separate soft tissue from bone

What are the layers of the meninges?
| 1. Dura mater 2. Arachnoid Mater 3. Pia Mater

What are the structures associated with the dura mater?
| Dural sheath and the epidural space (fat filled [cushions])

What are the structures associated with the arachnoid mater?
| Subarachnoid space (CSF and blood vessels)

What are the structures associated with the Pia Mater?
| Terminal filum

Protection of the Spinal Cord (cont)

What is the function of the dura mater?
| Outer covering-protection

What is the function of the arachnoid mater?
| Middle layer- subdural space

What is the function of the pia mater?
| Internal layer- thin membrane that is clingy and well vascularized (nourishing)

What are the functions of CSF?
| Cushion/floats CNS, removes waste, and circulates nutrients

Nervous/Spinal Nerves

What is a nerve?
| Bundles of axons

What structures make up nerves?
| Epineurium (outer covering), perineurium (surrounds nerve fascicles), and endoneurium (surrounds individual nerve fiber)

What are ganglia?
| clusters of cell bodies NOT in CNS

What are spinal nerves?
| 31 pairs: 8 cervical, 12 thoracic, 5 lumbar, 5 sacral, and 1 coccygeal

What are the general structures of spinal nerves?
| Rootlets, ventral root, dorsal root, and dorsal root ganglion

What is a nerve plexus?
| network/web of nerves

What are the major plexuses?
| Cervical plexus (C1-C4), Brachial plexus (C5-T1), Lumbar plexus (L1-L5), Sacral plexus (L4-S4)

Nervous/Spinal Nerves (cont)

What are the major nerves of the cervical plexus?
| Phrenic nerve-diaphragm

What are the major nerves of the brachial plexus?
| Axillary, radial, median, and ulnar

What are the major nerves of the lumbar plexus?
| Femoral and obturator

What are the major nerves of the sacral plexus?
| Sciatic nerve (tibial, fibular)

What does the cervical plexus innervate?
| Skin and muscles of the neck

What does the brachial plexus innervate?
| Neck, axilla, and the arm

What does the lumbar plexus innervate?
| Anterior and medial thigh

What does the sacral plexus innervate?
| Posterior thigh and the lower limb

What is a reflex?
| a response to a stimulation

What are the characteristics of a reflex and how does it work?

| 1. Stimulation (requires) 2. Fast (spinal cord and back) 3. Involuntary 4. Stereotyped (every time you do it, you get the same response)

The Brain

What are the main functions of the brain?

| 1. Initiates voluntary and involuntary movement 2. Interprets and integrates sensory stimulation 3. Consciousness and cognitive function 4. Controls basic life sustaining activities

The Brain (cont)

How is the brain organized?

Cerebrum, Cerebellum, Diencephalon, and Brain Stem

Describe the layers of protection for the brain

1. Skull 2. Meninges 3. CSF 4. Blood Brain Barrier

What are ventricles?

open chambers in the brain

List the order of the circulation through the ventricles

Starts in lateral ventricles, continues to the third ventricle, continues into the fourth ventricle, and goes into central canal of the spinal cord

The Brainstem

Where is the brainstem located?

at the base of the brain

What structures make up the brain stem?

Pons, medulla oblongata, and midbrain

What structures make up the medulla oblongata and where is it located?

Nuclei and tracts, located continuous with the spinal cord (caudal to stem)

What is the function of the medulla oblongata?

Relay info, cardiac center, vasomotor center, respiratory center, and convey info. Has cranial nerves IX-XII

What structures make up the pons and where is it located?

Bulge, cerebellar peduncles, tracts, and nuclei. Located between medulla and midbrain

The Brainstem (cont)

What is the function of the pons?

Carry signals up and down brainstem and connect right and left cerebellar hemispheres. Has cranial nerves V-VII

What structures make up the midbrain and where is it located?

Nuclei, tectum (roof), cerebral aqueduct, tegmentum (floor), cerebral crura. Located in the rostral portion of the brainstem

What is the function of the midbrain?

Visual reflexes/integration, process/relay auditory signals, fine motor control, voluntary movement. Contains cranial nerves III and IV

The Diencephalon

Where is the diencephalon located?

Deep to the cerebrum, superior to the brainstem, and surrounds the third ventricle

What structures make up the diencephalon?

Thalamus, hypothalamus, and epithalamus

What is the function of the thalamus?

Gateway to cortex: filter/relay sensory info (all but smell), motor control (relay info between cerebrum and cerebellum), and memory and emotional

What is the function of the hypothalamus?

Main control center of ANS: regulates homeostasis (hormone secretion, thermoregulation, food/water intake, sleep/circadian rhythms, emotion and sexual responses), memory (involved in memory formation)

The Diencephalon (cont)

What is the function of the epithalamus?

Sleep-wake cycle (circadian/seasonal cycles) and relay

The Cerebellum

Where is the cerebellum located?

Inferior/posterior to cerebrum, dorsal to pons

What structures make up the cerebellum?

Cerebellar hemispheres, cortex, folia (folds), arbor vitae (white matter), deep nuclei, cerebellar peduncles

What is the function of the cerebellum?

Subconscious evaluation of sensory input, coordinate and smooth movements, maintain posture and equilibrium, some cognitive skills (muscle memory)

The Cerebrum

What are the major structures that make up the cerebrum?

Cerebral cortex, cerebral white matter, nuclei, right and left hemispheres (separated by the longitudinal fissure and connected by the corpus callosum) and the transverse fissure (separates the cerebrum and cerebellum)

Describe the association tracts

one part of a hemisphere to another

The limbic system is...

the major emotion and learning center

What are functional areas of the cerebral cortex

Localization of specific functions



By **katwalker11**

cheatography.com/katwalker11/

Published 1st April, 2021.

Last updated 30th March, 2021.

Page 3 of 4.

Sponsored by **ApolloPad.com**

Everyone has a novel in them. Finish

Yours!

<https://apollopod.com>

The Cerebrum (cont)

What are the two specific functional areas of the cerebral cortex?

The primary cortex (sensory and motor) and the association cortex

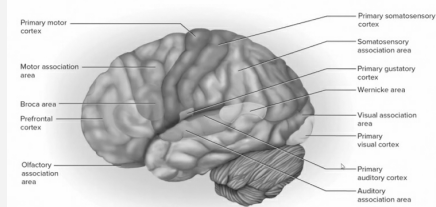
What are cranial nerves?

Nerves that arise directly from the brain (primarily base)

What are the different types of cranial nerves?

Motor: III, IV, VI, XI, XII **Sensory:** I, II, VIII and **Mixed:** V, VII, IX, X

Functional Areas Image



LOOK AT NOTES FOR IN DEPTH DESCRIPTION OF FUNCTIONAL AREAS

Autonomic Nervous System

What are the functions of the ANS?

Homeostasis aka regulation

What are the divisions of the ANS?

Sympathetic and Parasympathetic nervous systems

What is the function of the sympathetic nervous system?

Fight or flight

What is the function of the parasympathetic nervous system?

Rest and digest (homeostasis)

Autonomic Nervous System (cont)

What structures are associated with the sympathetic NS?

Smooth muscle in blood vessels, skin (raises hairs), sweat glands, and adrenal glands (epinephrine and norepinephrine secretion)

What structures are associated with the parasympathetic NS?

head/neck/thorax/abdomen and the digestive tract & pelvic organs

How do the sympathetic and parasympathetic divisions differ?

Sympathetic division has short preganglionic fibers and long postganglionic fibers while the **parasympathetic division** has long preganglionic fibers and short postganglionic fibers

How does the sympathetic and parasympathetic divisions differ from the somatic motor division?

The somatic motor division only has one ganglionic fiber

What is dual innervation?

sympathetic and parasympathetic divisions have antagonistic effects in working together

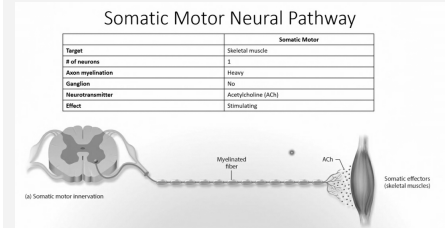
What is the enteric nervous system?

Nerve plexuses embedded in the wall of the digestive tract

What is the function of the enteric nervous system?

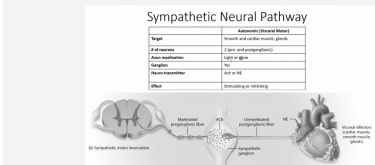
Motility and secretion of enzymes/acids

Somatic Neural Pathway



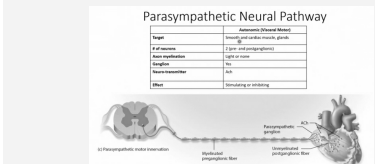
Use this and following images to describe the differences with somatic motor and autonomic systems

Sympathetic Neural Pathway



Use previous image and following image to contrast differences

Parasympathetic Neural Pathway



Use previous images to contrast