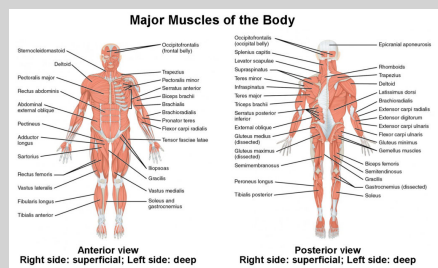


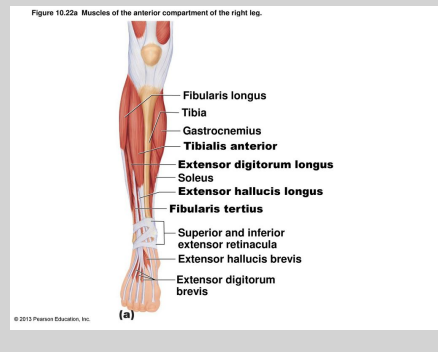
Naming Skeletal Muscles

- Muscle location
 - bone or body region with which muscle associated
- Muscle shape
 - e.g., deltoid muscle (deltoid = triangle)
- Muscle size
 - e.g., maximus (largest), minimus (smallest), longus (long)
- Direction of muscle fibers or fascicles
 - e.g., rectus(fibers run straight), transversus (fibers run at right angles), and oblique (fibers run at angles to imaginary defined axis)

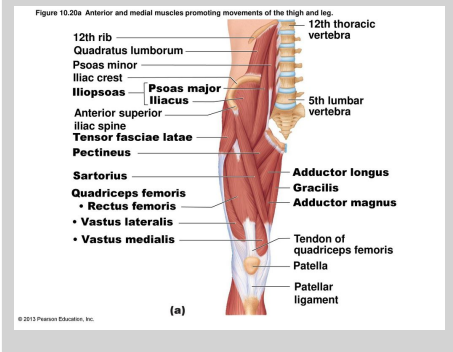
Naming Skeletal Muscles



Naming Skeletal Muscles



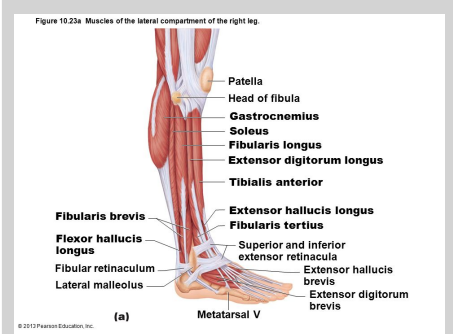
Naming Skeletal Muscles



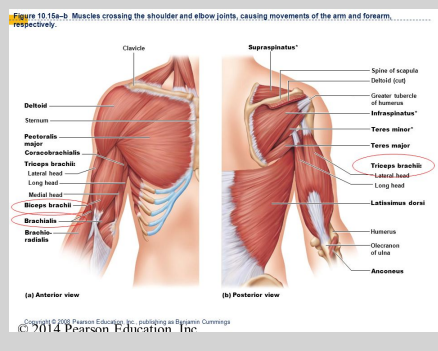
Naming Skeletal Muscles

- Number of origins
 - e.g., biceps(2 origins) and triceps (3 origins)
- Location of attachments
 - named according to point of origin and insertion (origin named first)
- Muscle action
 - named for action they produce, e.g., flexor or extensor
- Several criteria can be combined, e.g., extensor carpi radialis longus

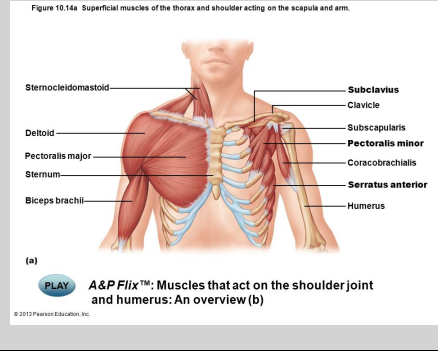
Naming Skeletal Muscles



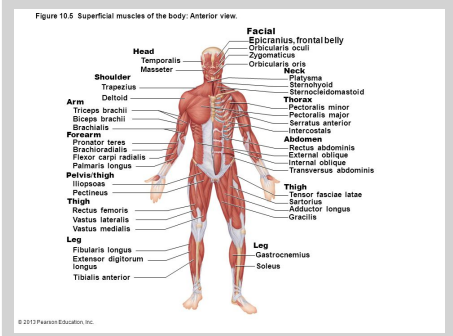
Naming Skeletal Muscles



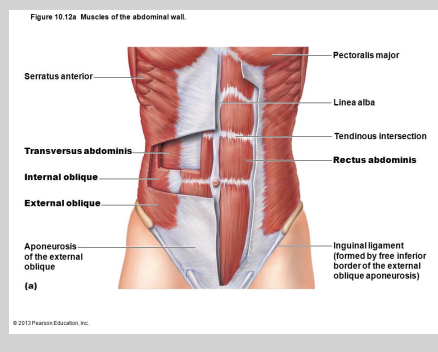
Naming Skeletal Muscles



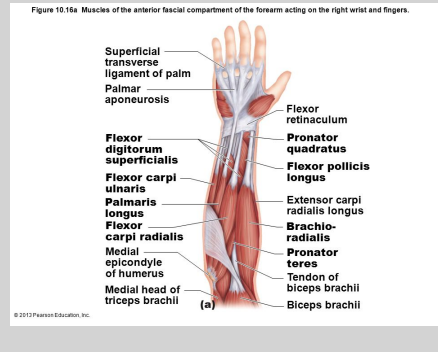
Naming Skeletal Muscles



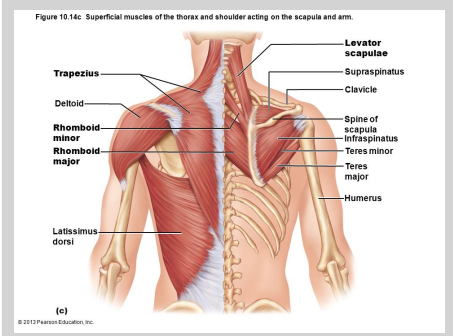
Naming Skeletal Muscles



Naming Skeletal Muscles

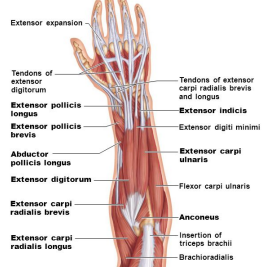


Naming Skeletal Muscles



Naming Skeletal Muscles

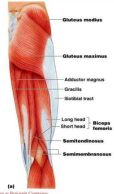Figure 10.17a Muscles of the posterior fascial compartment of the right forearm acting on the wrist and fingers.



© 2015 Pearson Education, Inc. (a)

Naming Skeletal Muscles

Movements of the Thigh at the Hip:
Other Movements

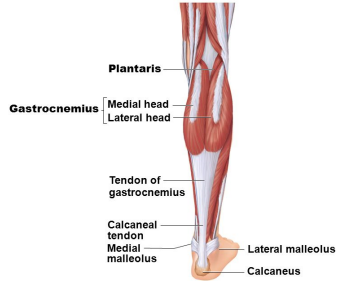


Copyright © 2015 Pearson Education, Inc. publishing as Benjamin Cummings

Figure 10.26a

Naming Skeletal Muscles

Figure 10.24a Muscles of the posterior compartment of the right leg.



© 2015 Pearson Education, Inc.

(a) Superficial view of the posterior leg.

C

By [jjovann](https://cheatography.com/jjovann/)
cheatography.com/jjovann/

Not published yet.
Last updated 31st October, 2018.
Page 2 of 2.

Sponsored by [Readability-Score.com](https://readability-score.com)
Measure your website readability!
<https://readability-score.com>