

Skeletal Anatomy: Upper Limb Joints

Sternoclavicular joint Diarthrotic, synovial, gliding/p-lanar

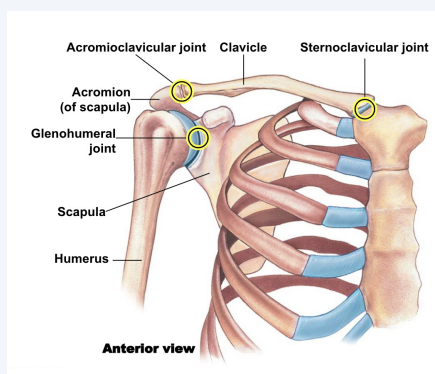
Shoulder joint

Elbow Joint (humer-oulnar joint) Diarthrotic, synovial, hinge

Superior and Inferior radioulnar joints Diarthrotic, synovial, pivot

Wrist joint

Pectoral girdle joints



Sternoclavicular joint

Sternum + clavicle

*Only bony attachment of upper limb to axial skeleton

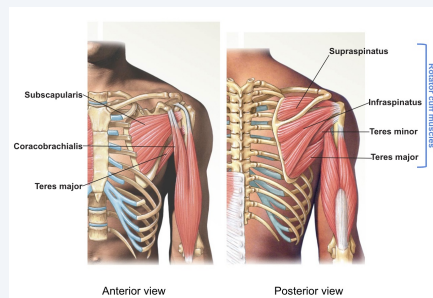
Acromioclavicular Joint

Acromion process + clavicle

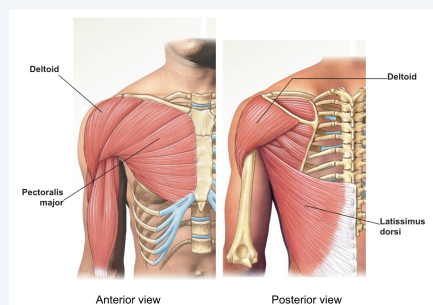
Glenohumeral joint

Glenoid fossa + humerus

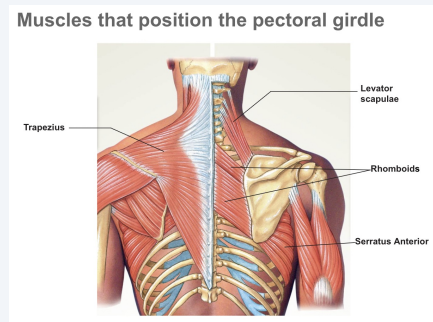
Synergists and fixators of arm at shoulder



Prime movers of arm at shoulder



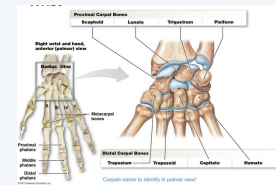
Muscles that position the pectoral girdle



Mnemonics

Carpal Bones So Long To Pinky, Here Comes The Thumb

Wrist Anatomy



Joint Terminology

Flexion Decreases angle between 2 bones

Extension Increases angle between 2 bones

Dorsiflexion Flexing or raising the dorsal surface of the foot

Plantar flexion flexing the plantar surface of the foot, depressing the foot and pointing the toes

Abduction movement away from the midline

Adduction Return to midline, movement to midline

Circumduction Moving a limb in circular motion



By heebiejibee

cheatography.com/heebiejibee/

Not published yet.

Last updated 2nd November, 2022.

Page 1 of 3.

Sponsored by [ApolloPad.com](https://apollopod.com)

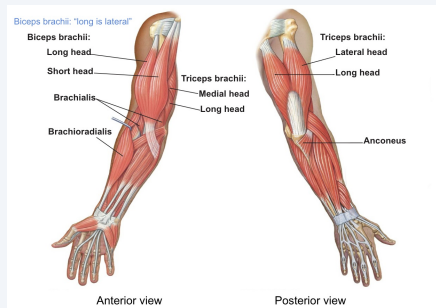
Everyone has a novel in them. Finish Yours!

<https://apollopod.com>

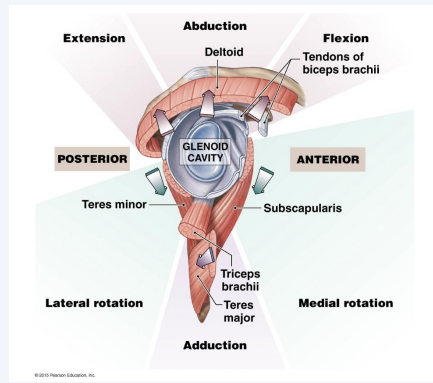
Joint Terminology (cont)

Rotation	Moving a bone around its axis (spinning), movement of a joint in a single rotary axis
Lateral rotation (External rotation)	Spinning a bone around its axis outward, away from the body
Medial rotation (Internal rotation)	Spinning a bone around its axis inward, toward the body
Pronation	Movement of forearm, dorsal side of hand facing forward
Supination	Reverse pronation, palm facing forward
Inversion	Turn foot in, rotate sole medially
Eversion	Turn foot out, rotate sole laterally

Movers of forearm at elbow joint



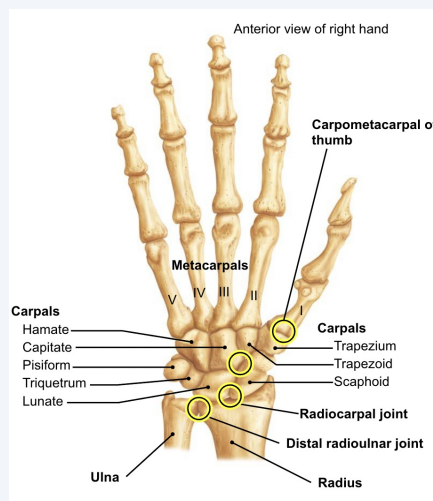
Synergists and fixators of arm at shoulder



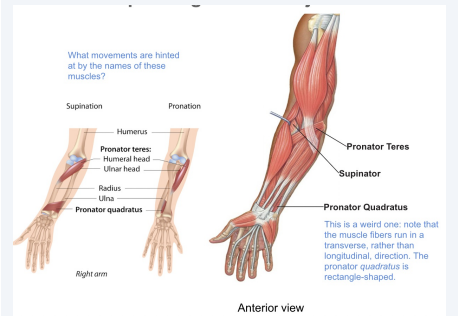
Wrist Joints

Radiocarpal Joint (true wrist)	Radius + scaphoid + lunate	Diarthrotic, synovial, condylar
Distal radioulnar	Distal end of radius + ulna	Diarthrotic, synovial, pivot
Intercarpal Joints	Adjacent carpals	Diarthrotic, synovial, planar/gliding
Carpometacarpal of thumb	Trapezium + first metacarpal	Diarthrotic, synovial, saddle

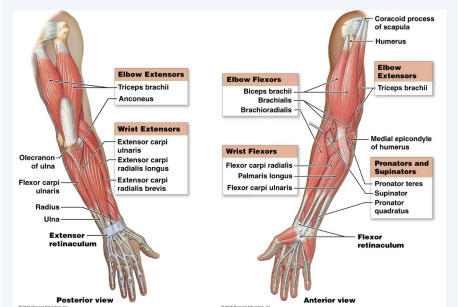
Wrist Joints Anatomy



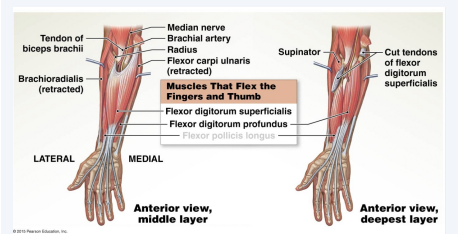
Movers of pivoting radioulnar joints



Movers of wrist and finger joints



Movers of wrist and finger joints



Movers of wrist and finger joints

