

Venous Anatomy

Blood from skin and SubQ tissue in legs flows into the superficial veins, then deep veins then to heart

Superficial Veins: Great saphenous, lesser saphenous

Deep veins: Inferior vena cava -> right common iliac -> internal iliac and external iliac -> femoral -> popliteal -> peroneal -> anterior and posterior tibial

Leg muscles assist with return of blood (muscle pump action)

Venous valves prevent retrograde flow of blood

Venous Disease Classification

CEAP classification

Clinical classification

C0	No visible or palpable signs of disease
C1	Telangiectasias or reticular veins
C2	Varicose veins
C3	Edema
C4a	Pigmentation or eczema
C4b	Lipodermatosclerosis or atrophic blanche
C5	Healed venous ulcer
C6	Active venous ulcer

S Symptomatic, including ache, pain, tightness, skin irritation, heaviness, muscle cramps, and other complaints attributable to venous dysfunction

A Asymptomatic

Etiologic classification

Ec	Congenital
Ep	Primary
Es	Secondary (post-thrombotic)
En	No venous cause identified

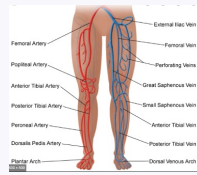
Anatomic classification

As	Superficial veins
Ap	Perforator veins
Ad	Deep veins
An	No venous location identified

Pathophysiologic

Pr	Reflux
Po	Obstruction
Pr, o	Reflux and obstruction
Pn	No venous pathophysiology identifiable

Venous Anatomy



History and Clinical Appearance

History: Medications- side effects of swelling?

Previous history of DVT, congenital valve weakness, ulcers, edema, prolonged standing, trauma, vein stripping or other procedures

Chief Complaint: Sense of tiredness, fatigue, heaviness in feet, night leg cramps (relief by walking or massage)

Signs of Venous Insufficiency: Varicose veins, telangiectasia, pitting edema, stasis dermatitis, hemosiderosis (brown iron complexes of hemosiderin often deposited into the tissue due to increased hydrostatic pressure forcing blood components to escape, brown staining results)

Chronic Insufficiency: Atrophic blanche, lipodermatosclerosis, venous ulcers

History and Clinical Appearance (cont)

Testing for Venous Disease: Brodie-Trendelenburg test, hand held doppler constant sound, photocell or air plethysmography, ambulatory venous pressure testing, venography

Venous stasis can occur from: -secondary to obstruction or insufficiency -thrombophlebitis may block venous drainage -valve damage contribute to incompetence -veins may be compressed due to tumour or fibrosis

Venous Disorders

Superficial Thrombophlebitis: Occurs when there is inflammation and thrombus within the superficial vein

Can occur following an infection, trauma, hypercoagulable states, oral contraceptives, procoagulant factors

Risk factors: prior history of superficial phlebitis, DVT, PE, recent surgery or pregnancy, prolonged immobilization, malignancy

Venous Disorders (cont)

Signs and Symptoms: Redness and warmth associated with vein, pain over vein, diffuse leg pain, edema, fever

Differentials: Baker's cyst, soft tissue injury, cellulitis, MSK pain, lymphangitis, neuritis, ruptured head of gastroc

Treatment: prevent progression into deep venous system, NSAIDs (for pain), anticoagulants (heparin), increase ambulation, gradient compression stockings (30-40-mmHg)

Deep Vein Thrombosis: Development of thrombus in the deep veins

Want to detect early to prevent fatal PE

If thrombus partially or completely blocks the flow of blood through the vein, blood begins to pool and build up venous hypertension

Venous Disorders (cont)

Risk Factors: Similar to superficial thrombophlebitis but also includes age >60, hypercoagulable states, obesity, history of DVT

Symptoms: Common site is the calf (post tib and peroneal veins), silent in 50% cases, progressive pulling sensation at back of leg, pain increases with ambulation, slight fever, swelling occurs distal to site of thrombus, distension of superficial veins, increase in temp distal to clot,

Causes: Virchow's triad

Prevention: Heparin, NSAIDs, gradient compression hose, increased ambulation

Venous Disorders (cont)

Treatment: if suspected refer to emerg! Bed rest x 1 week with legs elevated which stabilizes clot, elastic stocking to reduce swelling and protect superficial veins, 3-6 months limitation of prolonged standing, medications (fibrinolytic agents, anticoagulants, antibiotics)

Pulmonary Embolism

Embolus is a blockage in the blood flow to the lungs by blood clot or fat, air or tumor. Very dangerous when thrombus is torn from attachment. May cause pulmonary infarction

Risk Factors: same as DVT

Symptoms: Sudden, chest pain, shortness of breath, coughing, dizziness, fainting, anxiety/sweating.

MEDICAL EMERGENCY

Venous Disorders (cont)

Treatment: Thrombolytics, vein filter (prevents emboli from reaching lungs)

Chronic Venous Insufficiency

Venous hypertension caused by chronic venous reflux as a result of structural or functional abnormalities of veins

Leads to: Edema, protein exudation and deposition to skin, fibrosis and lipodermatosclerosis, stasis dermatitis, tissue hypoxia, leg ulcers

Venous Ulcer

Seen in lower third of leg (lateral or medial aspect), surrounding skin has signs of CVI, shallow ulcer, moist granulating base, sloping edges, cyanotic discoloration

Venous Disorders (cont)

Treatment: reduce venous hypertension by walking regimens, limb elevation, local wound care (manage moisture)

Virchow's Triad: 1. Stasis of blood 2. Increased blood coagulability 3. Vessel wall injury (alteration to vein wall)

Causes of Thrombi Formation: Old age, estrogen use, pregnancy, obesity, malignancy

Venous Disorder Management

Conservative

Elevation: Avoid high heels as they reduce venous emptying as muscle pump not activate. Raise feet above heart 15-30 mins several times/day. Place 2-3" block under legs

Exercise: Emphasize ankle plantarflexion, activate muscle venous pump. 30-60mins of PA

Medications: NSAIDs, vitamin C/E for symptom relief. Pentoxifylline may change course of disease

Compression Therapy:

Benefits: Reduce diameter of veins, increase flow velocity, decrease chance of thrombosis, improve lymphatic flow



Venous Disorder Management (cont)

Types: Elastic (stocking or bandaging), inelastic (garments or short stretch bandages), pneumatic compression

Classes: *Class 1:* 20-30mmHg for aching, swelling, telangiectasia, varicose veins (to start/asymptomatic)

Class 2: 30-40mmHg for symptomatic varicose veins, CVI, post ulcer

Class 3: 40-50mmHg for CVI, post ulcer

Class 4: 50-60mmHg for CVI, post ulcer, severe CVI not controlled by class 3

Surgical *Sclerotherapy:* remove obliteration of abnormal vessel that carry retrograde flow.

Other: Saphenofemoral bypass, prosthetic graft, valvular reconstruction

Venous Disorder Management (cont)

Vein Stripping: strip varicose veins (only option for saphenous vein)

*Elevating legs is contraindicated in CHF, gastroesophageal reflux, pulmonary disease and sleep apnea patients

*Compression therapy is contraindicated in patients with an ABI of 0.5 and below



By **happyfeet2020**

cheatography.com/happyfeet2020/

Published 16th March, 2022.

Last updated 16th March, 2022.

Page 3 of 3.

Sponsored by **ApolloPad.com**

Everyone has a novel in them. Finish Yours!

<https://apollopad.com>