

Background

Not an inflammatory condition
Occurs in synovial joints
Due to genetic factors, overuse, and injury

Presentation

Joint pain
Stiffness for <30mins - worse with activity
Crepitus
Limited range of movement

Commonly Affected Joints

Hips
Knees
SI joints
DIPs + MCP
Wrist
Cervical spine

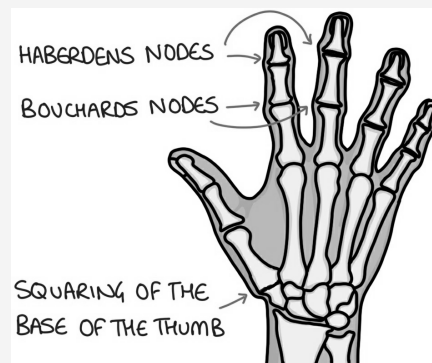
Complications of THR

Neurovascular injury (external iliac)
Infection
Dislocation
Periprosthetic fracture
Loosening of implant + polyethylene wear, implant failure

Risk Factors

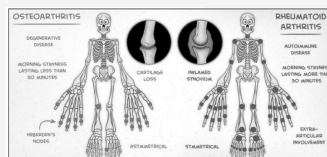
Obesity
Age
Occupation
Trauma
Female
Family history

Hand Signs

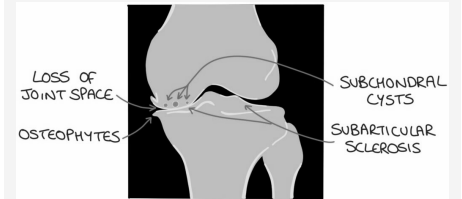


Heberden's nodes (DIP)
Bouchard's nodes (PIP)
Squaring of thumb (CMC)
Weak grip
Reduced range of motion

Difference Between OA and RA



Xray Changes (LOSS)



Diagnosis

No investigations needed if:
Patient over 45
Has typical activity-related pain
No morning stiffness
Stiffness lasts <30 mins

Management

1st line Patient education, physio, OT, orthotics
2nd line **Analgesia**
PO paracetamol + topical NSAIDs
Add PO NSAIDs (+ PPI)
Opiates (codeine, morphine)
3rd line Intra-articular steroid injections
4th line Joint replacement

C

By **ellieacook**
cheatography.com/ellieacook/

Published 29th July, 2022.
Last updated 28th July, 2022.
Page 1 of 1.

Sponsored by **CrosswordCheats.com**
Learn to solve cryptic crosswords!
<http://crosswordcheats.com>