

Telencephalon

The telencephalon, the largest brain division, includes the cerebral cortex, basal ganglia, and limbic system, governing conscious thought, perception, emotions, and voluntary motor functions.

Cerebral Cortex

Responsible for conscious thought, perception, reasoning, and voluntary motor control. - Divided into different lobes, each with specific functions: - Frontal lobe: Involved in motor control, decision-making, and executive functions. - Temporal lobe: Responsible for auditory processing and memory. - Parietal lobe: Processes sensory information and spatial awareness. - Occipital lobe: Primarily handles visual processing.

Basal Ganglia

Group of subcortical nuclei that play a crucial role in motor control and procedural learning. - Dysfunction can result in movement disorders like Parkinson's disease.

Limbic System

Collection of structures that regulate emotions, motivation, learning, and memory. - Key components include: - Amygdala: Responsible for emotional processing, particularly fear and aggression. - Hippocampus: Crucial for memory formation, especially in the consolidation of long-term memories. - Hypothalamus: Regulates emotional and

Limbic System

The limbic system is involved in the formation of emotional memories and the influence of emotional responses on decision-making.

Diencephalon

The diencephalon, composed of the thalamus and hypothalamus, regulates sensory information relay and internal bodily functions, maintaining homeostasis.

Thalamus

Acts as a relay station for sensory information.

Hypothalamus

Regulates the internal environment of the body, including temperature, salt concentration, hormones, and more. - Maintains homeostasis by adjusting physiological conditions. - Controls various functions like body temperature, appetite, body weight, heart rate, and blood pressure. - Connects the endocrine and nervous systems by interacting with the pituitary gland.

Mesencephalon

The mesencephalon, located in the brainstem, contains the tectum (responsible for sensory processing) and tegmentum (associated with motor control and pain perception).

Tectum

Composed of two pairs of bumps: inferior colliculi

Tegmentum

Contains the periaqueductal gray (mediates analgesic effects), substantia nigra (sensorimotor system), and red nucleus (sensorimotor system).

Metencephalon

The metencephalon comprises the pons (regulates autonomic functions and connects brain regions) and the cerebellum (coordinates voluntary muscle movements and posture, with cognitive functions).

Pons

Major division of the metencephalon. - Regulates various autonomic functions such as breathing and sleep.

Cerebellum

Large, convoluted structure on the brain stem's dorsal surface. - Coordinates voluntary muscle movements, posture, and balance. - Also involved in cognitive functions, including decision-making and language.

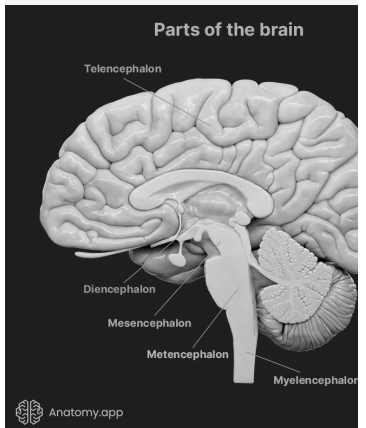
Myelencephalon

The myelencephalon is composed of tracts for signal transmission between the brain and the body, while the reticular formation within it plays a role in arousal, sleep, attention, and autonomic functions.

Reticular Formation in Myelencephalon

Complex network of about 100 tiny nuclei occupying the central core of the brain stem. -

Figure 1.1



autonomic functions, including hunger, thirst, and circadian rhythms.

(auditory) and superior colliculi (visual-motor). - Involved in directing the body's orientation toward or away from visual stimuli.

Contains a mixture of cell bodies and axons. - Functions as the reticular activating system, playing a role in arousal. - Involved in various functions, including sleep, attention, movement, muscle tone maintenance, cardiac, circulatory, and respiratory reflexes.



By **drax**
cheatography.com/drax/

Published 22nd October, 2023.
Last updated 22nd October, 2023.
Page 1 of 2.

Sponsored by **Readable.com**
Measure your website readability!
<https://readable.com>