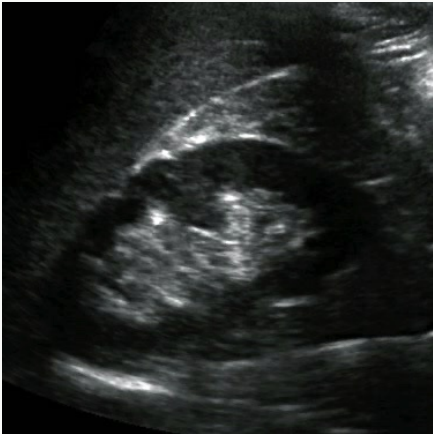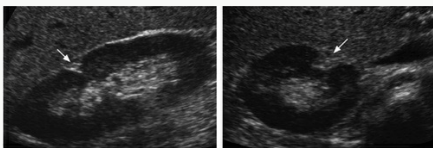


### Hypertrophied Column of Bertin



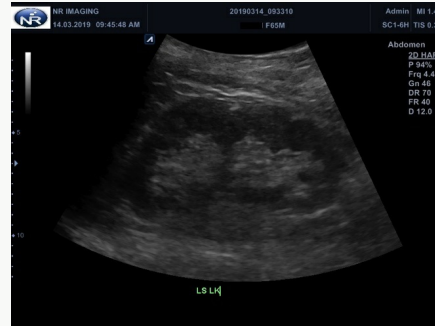
Column of Bertin extends into sinus.

### Junctional Parenchymal Defect



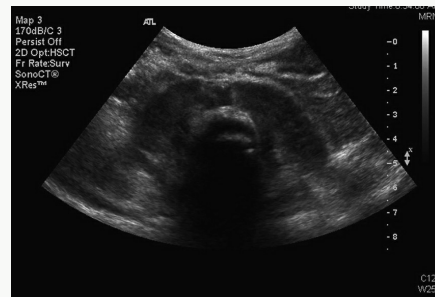Triangular echogenic area located anterior and superior to the kidney.

### Duplicated Collecting System



The sinus is divided into 2. With this in mind, 2 ureters can develop.

### Horseshoe Kidney



Kidneys are connected; typically at the lower poles.



By Alyssabruestle1

[cheatography.com/alyssabruestle1/](https://cheatography.com/alyssabruestle1/)

Not published yet.

Last updated 28th November, 2022.

Page 1 of 1.

Sponsored by [Readable.com](https://readable.com)

Measure your website readability!

<https://readable.com>