

Male

Testes (plus epididymis and vas deferens)

Penis

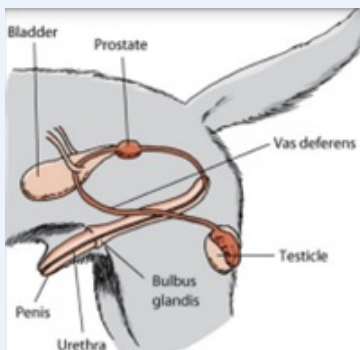
Prostate gland

Bulbourethral glands (cat/horse)

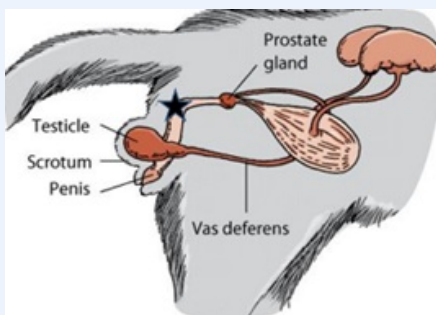
Bulbus glands (dog)

Vesicular glands (horse)

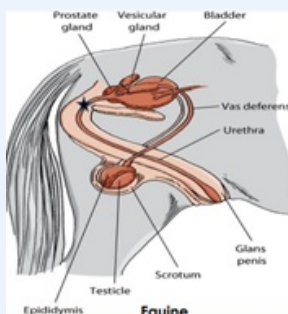
Canine



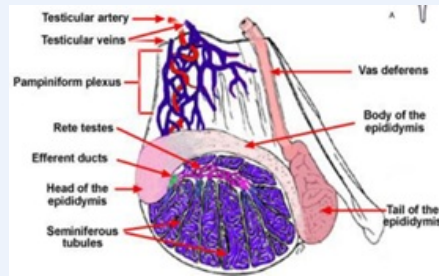
Feline



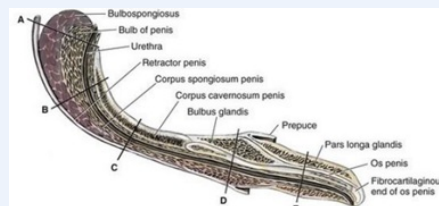
Equine



Testicle Anatomy



Penis Anatomy



Female

Ovaries

Oviducts (Fallopian tubes)

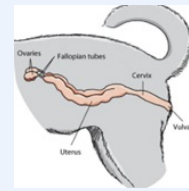
Uterus (Horns and body)

Cervix

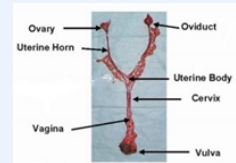
Vagina

Vulva

Canine and Feline



Canine and Feline



Equine

